

## AAP-Commissioned Review

### Bone Augmentation Techniques

Bradley S. McAllister\*<sup>†</sup> and Kamran Haghghat\*<sup>‡</sup>

**Background:** The advent of osseointegration and advances in biomaterials and techniques have contributed to increased application of dental implants in the restoration of partial and completely edentulous patients. Often, in these patients, soft and hard tissue defects result from a variety of causes, such as infection, trauma, and tooth loss. These create an anatomically less favorable foundation for ideal implant placement. For prosthetic-driven dental implant therapy, reconstruction of the alveolar bone through a variety of regenerative surgical procedures has become predictable; it may be necessary prior to implant placement or simultaneously at the time of implant surgery to provide a restoration with a good long-term prognosis. Regenerative procedures are used for socket preservation, sinus augmentation, and horizontal and vertical ridge augmentation.

**Methods:** A broad overview of the published findings in the English literature related to various bone augmentation techniques is outlined. A comprehensive computer-based search was performed using various databases that include Medline and PubMed. A total of 267 papers were considered, with non-peer-reviewed articles eliminated as much as possible.

**Results:** The techniques for reconstruction of bony defects that are reviewed in this paper include the use of particulate bone grafts and bone graft substitutes, barrier membranes for guided bone regeneration, autogenous and allogenic block grafts, and the application of distraction osteogenesis.

**Conclusions:** Many different techniques exist for effective bone augmentation. The approach is largely dependent on the extent of the defect and specific procedures to be performed for the implant reconstruction. It is most appropriate to use an evidenced-based approach when a treatment plan is being developed for bone augmentation cases. *J Periodontol* 2007; 78:377-396.

#### KEY WORDS

Augmentation; bone graft; dental implants; membranes; regeneration.

*Periodically, the Board of Trustees of the American Academy of Periodontology identifies the need for articles on a specific topic and requests the Editor-in-Chief of the Journal of Periodontology to commission such an article. The selected author is solely responsible for the content, and the manuscript is peer reviewed, like all other Journal articles. The Academy's Board of Trustees does not review or approve the manuscript prior to publication, and the content of the article should not be construed as Academy policy.*

**B**ones and teeth are the only structures within the body where calcium and phosphate participate as functional pillars. Despite their mineral nature, both organs are vital and dynamic. The histogenesis of bone is directly from mesenchymal connective tissue (intramembranous bone formation) or from preexisting cartilage (endochondral bone formation). Intramembranous bones are found in the mandibulo-craniofacial complex, ilium, clavicle, and scapula.<sup>1</sup> The intramembranous bone formation pathway is used when intraoral bone augmentation techniques are used by the surgeon.<sup>2</sup>

Bone is composed of the outer cortical layer and the inner cancellous layer. The dense haversian systems of cortical bone provide skeletal strength. Interposed between the cortices is a three-dimensional lattice network of trabeculae that acts as a reservoir for active bone metabolism. This bony architecture is dynamic with a continuous remodeling to repair and shape the bone to ensure renewal of form and function.

\* Private practice, Tigard, OR.

<sup>†</sup> Department of Periodontology, School of Dentistry, The University of Texas Health Science Center at San Antonio, San Antonio, TX.

<sup>‡</sup> Department of Periodontology, School of Dentistry, Oregon Health Sciences University, Portland, OR.

The principles of osteogenesis, osteoconduction, and osteoinduction can be used to optimize therapeutic approaches to bone regeneration.<sup>3</sup> Osteogenesis has been described as the direct transfer of vital cells to the area that will regenerate new bone. Osteoconduction embraces the principle of providing the space and a substratum for the cellular and biochemical events progressing to bone formation. The space maintenance requirement for many of the intraoral bone augmentation procedures allows the correct cells to populate the regenerate zone.<sup>4</sup> Osteoinduction embodies the principle of converting pluripotential, mesenchymal-derived cells along an osteoblast pathway with the subsequent formation of bone. This concept was established in 1965, with heterotopic ossicle formation induced by the glycoprotein family of morphogens known as the bone morphogenetic proteins (BMPs).<sup>5</sup> Therapeutic bone reconstruction approaches use some or all of these principles in an attempt to maximize the clinical bone augmentation results.

### BONE AUGMENTATION APPLICATIONS

Bone augmentation techniques may be used for the applications of extraction socket defect grafting, horizontal ridge augmentation, vertical ridge augmentation, and sinus augmentation. To maximize the results for each of these applications, a variety of different techniques is employed. They include particulate grafting, membrane use, block grafting, and distraction osteogenesis, either alone or in combination.

When considering the various modalities of treatment for the prosthetic replacement of teeth following tooth loss, the end goal of therapy is to provide a functional restoration that is in harmony with the adjacent natural dentition. Resorption of alveolar bone is a common sequela of tooth loss and presents a clinical problem, especially in the esthetic zone. This may jeopardize the esthetic outcome and compromise functional and structural aspects of treatment. To achieve this goal of therapy, it is desirable to provide treatment that will aim at preservation of the natural tissue contours in preparation for the proposed implant prosthesis.<sup>6</sup> However, augmentation and regeneration of the lost bone often are necessary. With the current increase in the use of dental implants for restoration of partial and complete edentulism, more emphasis is being placed on preservation of the alveolar ridge to ensure optimal implant placement and prosthetic treatment outcome. To satisfy the goals of implant dentistry, hard and soft tissues need to be present in adequate volumes and quality. To achieve an optimized restorative result, clinicians are often faced with placing implants in anatomically less favorable positions with regards to the quantity of available bone. This has necessitated development of techniques and materials that promote predictable regenerative treatment. Regeneration refers to the

reconstitution of a lost or injured part by complete restoration of its architecture and function.<sup>7</sup> Augmentation of bone volume has been assisted through different methods, including use of growth and differentiation factors, particulate and block grafting materials, distraction osteogenesis, and guided bone regeneration (GBR). These techniques resulted in comparable long-term implant survival.<sup>8</sup>

Alveolar ridge deformities are classified according to their morphology and severity.<sup>9,10</sup> A classification for alveolar ridge defects has been described to standardize communication among clinicians in the selection and sequencing of reconstructive procedures designed to eliminate these defects.<sup>9</sup> A class I defect has bucco-lingual loss of tissue with normal ridge height in an apico-coronal direction. A class II defect has apico-coronal loss of tissue with normal ridge width in a bucco-lingual direction. A class III defect has a combination bucco-lingual and apico-coronal loss of tissue resulting in loss of height and width. Thus, the bone augmentation technique employed to reconstruct these different ridge defects is dependent on the horizontal and vertical extent of the defect. The predictability of the corrective reconstructive procedures is influenced by the span of the edentulous ridge and the amount of attachment on the neighboring teeth; typically, reconstructive procedures are less favorable in defects that exhibit horizontal and vertical components. The extent of the anticipated bone resorption varies between the mandible and maxilla and at sites within the arches.

### Socket Preservation Application

In the anterior maxilla, where the buccal plate often is extremely thin and friable, consistent bone resorption is found after extraction.<sup>11</sup> To minimize bone resorption, less traumatic extraction techniques with socket augmentation, using a variety of particulate bone graft materials with and without membrane barriers, were reported that demonstrated significantly reduced alveolar ridge dimensional changes associated with these preservation techniques.<sup>12-21</sup> Grafting of extraction sockets at the time of extraction may not always be beneficial. Animal and human studies showed that extraction sockets with completely intact bony walls are capable of socket defect bone regeneration on their own.<sup>22-24</sup> Despite preservation of the alveolar ridge and socket dimensions through the use of a variety of bone graft materials, the dynamics of the extraction socket healing processes reportedly were altered.<sup>25</sup> Fibrous graft material encapsulation was shown following grafting of extraction sockets in the absence of barrier membranes that may influence the bone-implant contact following implant integration.<sup>25,26</sup> Multiple animal studies showed that defects of the original buccal plate do not heal completely without use of a grafting technique.<sup>27-29</sup>

Thus, in the anterior maxilla, grafting for space maintenance and ridge preservation may be beneficial.<sup>30</sup> In addition, for situations where the periapical bone or the socket walls are not intact, bone augmentation may be used to preserve the original anatomy of any location. Although socket preservation surgery is beneficial in some cases, soft tissue closure and graft containment are two of the difficulties associated with this procedure.<sup>30-32</sup>

To preserve the extraction socket architecture and to accelerate the timeline to final implant restoration, the technique of immediate implant placement at the time of extraction often is proposed. Immediate implant placement was shown to have a failure rate of <5%, which is comparable to delayed placement.<sup>15,31,32</sup> Many reports demonstrated successful outcome with GBR applied to dental implants placed in extraction sockets.<sup>15,33</sup> The immediate placement of implants into fresh extraction sockets in conjunction with bone augmentation has shown comparable success to that observed in delayed implant placement.<sup>15,31,34</sup> Several approaches were reported that included the use of expanded polytetrafluoroethylene<sup>§</sup> (ePTFE) membranes,<sup>15,31,35</sup> bioabsorbable membranes,<sup>36</sup> demineralized freeze-dried bone allograft (DFDBA),<sup>31,37,38</sup> freeze-dried bone allograft (FDBA),<sup>37</sup> bone autograft,<sup>25,39</sup> hard tissue replacement polymer,<sup>40</sup> connective tissue barriers,<sup>41,42</sup> bone xenograft, and hydroxyapatite (HA);<sup>38,43</sup> none showed a superior outcome to others. Membrane exposure was associated with higher bone resorption. Immediate postextraction implant placement should be considered only if implant stability can be achieved; otherwise, a staged approach is used. Conversely, immediate placement of implants into extraction sockets with a horizontal defect dimension (distance from bone to implant) <2 mm is amenable to predictable partial defect fill by appositional bone growth, without barrier membranes.<sup>34,39,44</sup> The degree of bone-implant integration is highly dependent on the gap present between the inner aspect of the socket and implant surface.<sup>45</sup> The degree of bone fill and the extent of implant thread exposure of immediate implants placed into extraction sockets have been evaluated.<sup>15,46</sup> The thread exposure for immediate implants was greater when complications, such as membrane exposure, occurred during healing.<sup>15</sup> Healing with immediate implants is similar to extraction sockets alone; however, the vascularity is compromised for the overlying soft tissue with the implant in place, resulting in potentially more soft tissue healing complications.<sup>46</sup>

### Ridge Augmentation Application

Critical-sized alveolar ridge defects in the horizontal and vertical dimensions may occur following tooth

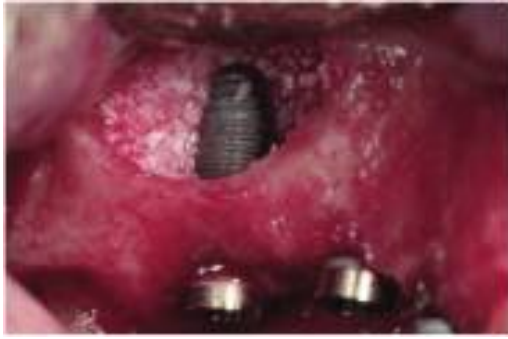loss, fractures, or pathologic processes. Such defects may compromise the ideal implant placement as prescribed prosthetically with an unfavorable outcome. Horizontal ridge augmentation was described with the use of a variety of different techniques and materials.<sup>47-51</sup> Although achieving comparable clinical outcomes for vertical ridge augmentation has been more challenging, success was demonstrated with the use of non-resorbable ePTFE membranes with autograft,<sup>52-55</sup> titanium mesh with particulate grafts,<sup>56</sup> forced tooth eruption,<sup>57</sup> autogenous block grafting,<sup>58</sup> and distraction osteogenesis.<sup>59,60</sup>

### Sinus Augmentation Application

The posterior maxilla creates a unique challenge when minimal bone height remains inferior to the sinus floor. The inadequate bone volume often encountered is a result of a combination of ongoing maxillary sinus pneumatization and normal postextraction bone atrophy. The residual ridge height was measured in the edentulous posterior maxilla, and 43% of the proposed implant sites had  $\leq 4$  mm of bone crestal to the sinus.<sup>61</sup> To compound the challenges in this area further, the posterior maxilla has a poorer bone quality compared to the mandible, with the highest percentage of type IV bone.<sup>62</sup> Implant therapy in the posterior maxilla often is accomplished using shorter length implants. When an unfavorable crown/root ratio is anticipated, augmentation of the alveolar bone height should be considered. In the absence of an intraoral component of vertical ridge deficiency, augmentation of the maxillary sinus floor through a modified posterior Caldwell-Luc procedure may be performed.<sup>63-66</sup> This involves a lateral approach via a trap door access to the maxillary sinus. Careful elevation of the Schneiderian membrane creates a defined space between itself and the sinus floor to receive the bone-grafting material of choice. No significant difference in the failure rate was found with simultaneous implant placement and sinus augmentation compared to a delayed two-stage approach (Fig. 1).<sup>67,68</sup> In humans, several techniques were reported for successful sinus augmentation, with average implant success rates  $\sim 92\%$ .<sup>68,69</sup>

As an alternative, sinus augmentation can be performed by a less invasive osteotome technique, where elevation of the sinus floor is performed by inward collapse of the residual crestal floor with specially designed osteotomes; this obviates the need for a trap door access.<sup>51,66,70-75</sup> Bone graft material can be introduced through the prepared osteotomy, if needed, with or without simultaneous implant placement. The amount of augmentation achieved by the osteotome technique was 3 to 5 mm. Dependent

§ Gore-Tex, W.L. Gore & Associates, Flagstaff, AZ.



**Figure 1.**

A direct lateral window approach sinus augmentation procedure with simultaneous implant placement.

on the proposed length of implant, a minimum preoperative ridge height of 5 mm is desired to achieve adequate elevation of the sinus floor without undue risk for perforation of the Schneiderian membrane.<sup>76</sup>

Although the lateral window approach has a more extensive literature support,<sup>77</sup> the approach is determined by anatomic factors, such as the preoperative alveolar bone height and width dimensions and access, as well as the extent of the desired augmentation. When bone of sufficient volume and quality for achieving primary implant stabilization is present at the time of sinus augmentation, a single-stage approach may be used where implant placement is performed simultaneously.<sup>67</sup> Survival of implants placed at the time of sinus augmentation using the lateral window approach is increased with crestal ridge heights >3 mm.<sup>78-80</sup>

Augmentation of the sinus has been described using a variety of grafting materials that include autogenous particulate bone graft,<sup>61,81,82</sup> DFDBA particulate,<sup>83,84</sup> anorganic bovine bone particulate,<sup>81,85,86</sup> non-resorbable HA,<sup>87</sup> autogenous block grafts,<sup>88</sup> and BMP-2.<sup>89</sup> The placement of bioabsorbable or non-resorbable barrier membranes over the lateral sinus window and graft material aided in graft containment, prevented soft tissue enclavation, and enhanced the implant success rate.<sup>90,91</sup> Histologic investigations of the regenerated bone following sinus augmentation procedures showed considerable variation in bone quality. Histomorphometric analysis of sinus graft biopsies revealed a large variation, typically 5% to 60%, in vital bone area.<sup>61,81,92-95</sup>

To evaluate for maxillary sinus pathology and to determine the anatomic features, such as residual bone, sinus topography, and septa locations, prior to initiation of a sinus augmentation procedure, a computer tomography scan evaluation may be performed.<sup>66,96,97</sup> Evidence of acute sinusitis,

chronic sinusitis, or other sinus pathology suggests the need to refer to the otolaryngologist for treatment prior to initiation of the sinus augmentation procedure.<sup>98</sup> Preoperative sinusitis was a positive predictive factor for the development of postoperative acute sinusitis.<sup>99</sup>

Although significant complications with sinus augmentation have a low incidence, the following have been reported: infection, bleeding, cyst formation, graft slumping, membrane tears, ridge resorption, soft tissue enclavation, sinusitis, and wound dehiscence.<sup>90,94,100-102</sup> In cases with smaller internal sinus angles, there was an increase in the incidence of membrane tears.<sup>81</sup> If the membrane tears, a bioabsorbable collagen membrane can be used to assist in graft containment. Antibiotic prophylaxis preoperatively and for 7 to 10 days postoperatively with amoxicillin or clavulanic acid and amoxicillin were suggested.<sup>87,102,103</sup> Although these studies did not evaluate treatment without antibiotics, antibiotic prophylaxis reduced the infection rate for oral surgery procedures.<sup>104</sup>

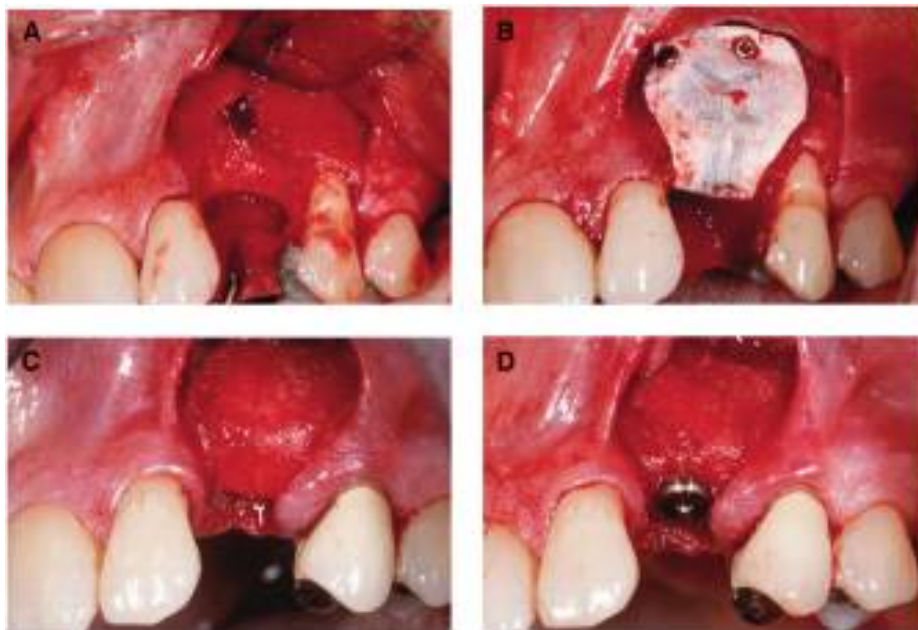## BONE AUGMENTATION TECHNIQUES

The remainder of this article reviews the various techniques available for augmenting the quantity of the available deficient alveolar bone. These include, but are not limited to, the use of barrier membranes for GBR, particulate grafting materials, onlay block grafting techniques, distraction osteogenesis, ridge split techniques, the future applications of molecular factors to stimulate the rate of bone formation, and in severe defects, a combination staged approach of these techniques.

### *Bone Augmentation With Barrier Membrane Technique*

The concept of GBR was described first in 1959 when cell-occlusive membranes were employed for spinal fusions.<sup>105</sup> The terms “guided bone regeneration” and “guided tissue regeneration” (GTR) often are used synonymously and rather inappropriately. GTR deals with the regeneration of the supporting periodontal apparatus, including cementum, periodontal ligament, and alveolar bone, whereas GBR refers to the promotion of bone formation alone. GBR and GTR are based on the same principles<sup>106,107</sup> that use barrier membranes for space maintenance over a defect, promoting the ingrowth of osteogenic cells and preventing migration of undesired cells from the overlying soft tissues into the wound. Protection of a blood clot in the defect and exclusion of gingival connective tissue and provision of a secluded space into which osteogenic cell from the bone can migrate are essential for a successful outcome. The sequence of bone healing is not only affected by invasion of





### Figure 2.

**A)** Preoperative view of defect, 2 months postextraction, demonstrating both vertical and horizontal deficiencies in site #11. **B)** Adaptation of a titanium-reinforced membrane secured with stabilization pins. **C)** Reconstructed ridge deficiency allowing ideal tri-dimensional implant placements **(D)**.

these devices should feature characteristics necessary to attain specific goals when applied in GBR, including material biocompatibility and stability over the required duration of barrier function, space maintenance, exclusion of undesired cell ingrowth, and ease of use. Non-resorbable barriers are available as ePTFE, titanium reinforced ePTFE, high-density PTFE, or titanium mesh.<sup>49,116-119</sup> An evidence-based outcomes assessment for the different GBR approaches summarized the effectiveness of the technique in bone augmentation.<sup>49</sup> The porous ePTFE membranes (guided tissue augmentation material, GTAM) have a central cell occlusive region and an outer cell adherent region; they can be obtained with titanium ribs for use in larger defects to enhance their space maintenance properties (Fig. 2).<sup>118</sup>

non-osteogenic tissue, but more so by the defect size and morphology. A predictable intraoral GBR approach was developed in the late 1980s and early 1990s;<sup>108-110</sup> it has become a predictable surgical methodology to enhance new bone formation in peri-implant bone deficiencies and alveolar ridge augmentation, albeit requiring excellent surgical skills and being highly technique sensitive. The technique can be applied to extraction socket defects, horizontal and vertical ridge augmentation, and the correction of dehiscence and fenestration defects around implants. Successful vertical ridge augmentation with the GBR technique, using titanium reinforced ePTFE membranes, was shown in human and animal studies.<sup>54,111</sup> Both studies demonstrated that up to 4 mm of vertical augmentation was feasible without the use of any grafting material under the membranes. Addition of bone graft material to the GBR technique increases the amount of achievable vertical regeneration.<sup>55</sup> In follow-up prospective studies, survival of prosthetically loaded implants placed in ridges that were augmented vertically with various GBR techniques, using non-resorbable membranes with or without a bone graft, demonstrated comparably favorable outcomes as implants placed in native or horizontally augmented bone, with an overall success rate of 97.5%.<sup>112-115</sup>

A variety of non-resorbable and bioabsorbable barrier membranes has been used in bone augmentation with the GBR concept. From a manufacturing aspect,

The ePTFE membrane has been studied extensively in animals and humans<sup>47,49,109,110</sup> and is considered a standard for bone augmentation.<sup>120</sup> The high-density PTFE membranes<sup>||</sup> are entirely cell occlusive, show minimal inflammation when exposed to the oral cavity, do not integrate with the tissue for membrane stabilization, and were effective in a rat mandible model and in human case reports.<sup>117,121</sup> The use of titanium mesh as a barrier maximizes graft containment and eliminates the space maintenance collapse problems that are associated with conventional membranes.<sup>119,122</sup> The pattern of bone regeneration involves angiogenesis and ingress of osteogenic cells from the defect periphery toward the center to create a well-vascularized granulation tissue. This provides a scaffold for woven bone proliferation and bone apposition within the defect.<sup>123</sup> The size of the defect influences the bone healing capacity. In circumstances where the defect is too large to generate a biomechanically stable central scaffold, bone formation is limited to the marginal stable zone with a central zone of disorganized loose connective tissue. Thus, combined use of bone grafts or bone replacement substitutes with barrier membranes are advocated in bone regeneration of larger defects. Repair of osseous defects closely resembles appositional bone growth during which the woven bone construction

|| Gore-Tex, W.L. Gore & Associates.

acts as a template for lamellar bone formation. As in the healing pattern observed in extraction sockets, organization of the blood clot is followed by ingrowth of vascular tissue and deposition of woven bone. Reinforcement of this disorganized bone structure is accomplished by lamellar bone formation, which, in turn, is remodeled soon after as is evident by the presence of secondary osteons.

Maintenance of primary wound closure throughout the healing period is critical to the outcome of GBR. Despite the success demonstrated with ePTFE membranes in GBR application, complications of soft tissue dehiscence with membrane exposure and infection impaired the outcome of therapy with a decreased gain in bone fill reported.<sup>124,125</sup>

To overcome some of the limitations of non-resorbable membranes, such as the need for a second surgical procedure for their removal with the added risk of loss of some of the regenerated bone further to flap reflection, they largely have been replaced with bioabsorbable membranes.<sup>15,35,51,126-129</sup> Bioabsorbable barrier membranes currently in clinical use fall into two broad categories: natural or synthetic. Natural products are made of various types of collagen of animal origin. Synthetic products are made of aliphatic polyesters, primarily poly(lactic) and poly(glycolic) acid copolymers. They differ in their mode of resorption; collagen products undergo enzymatic degradation, whereas synthetic barriers are degraded by hydrolysis.<sup>130</sup> Like the non-resorbable membranes, bioabsorbable membranes can experience premature soft tissue dehiscences and exposures. However, communication with the oral cavity accelerates their resorption rate, and, thus, reduces prolonged contamination of the regenerated bone matrix. Although collagen barriers offered improved soft tissue response, they lacked the ability to maintain adequate defect space.<sup>27,131,132</sup> Collagen barriers promoted human osteoblast proliferation and alkaline phosphate activity.<sup>133</sup> Degradation of synthetic copolymers elicited a soft tissue inflammatory response that resulted in resorption of some of the regenerated bone.<sup>134</sup> In addition, there is high variability and lack of control over the rate of membrane resorption, which is influenced by factors such as the local pH and material composition.

Bioabsorbable barriers have been developed in synthetic polymer forms<sup>¶#\*\*††‡‡</sup> (including [polyglactin 910] mesh),<sup>§§</sup> collagen,<sup>|||¶¶###\*\*††‡‡‡‡§§§</sup> calcium sulfate,<sup>||||</sup> or intact connective tissue.<sup>¶¶¶36,51,135-138</sup> One of the collagen membranes<sup>###</sup> had a barrier function in animal studies up to 4 months.<sup>27</sup> These collagen products<sup>\*\*\*†††‡‡‡‡‡‡</sup> are used only for initial graft material containment and clot stabilization because of their rapid 1- to 2-week resorption time.<sup>30,135,138-140</sup> A polymer membrane<sup>§§§§</sup> was evaluated and found

to be successful in humans for use as a GBR barrier in combination with particulate grafting.<sup>90,136</sup> Because of a lack of rigidity, in all but the smallest defects, most of these bioabsorbable membranes must be used in combination with a graft material for space maintenance in bone augmentation applications.<sup>27</sup> One collagen membrane<sup>|||||</sup> was studied in clinically relevant implant defects in animals<sup>27</sup> and was evaluated around implants in humans.<sup>51</sup> This membrane performed in a manner similar to ePTFE with respect to defect fill and showed less soft tissue exposure problems compared to the ePTFE control group.

Choice of membrane depends largely on the required duration of membrane function for tissue regeneration (~6 months).<sup>141,142</sup> The volume of regenerated bone generally is more encouraging with non-resorbable ePTFE membranes than with bioabsorbable membranes<sup>143,144</sup> Contrasting findings also have been reported. The non-resorbable ePTFE (GTAM) membrane was compared to a bioabsorbable collagen barrier<sup>¶¶¶¶</sup> in 84 defects. An average of 92% bone fill was achieved with the collagen membrane/xenograft compared to 78% with ePTFE/xenograft.<sup>51</sup> When no premature membrane exposure occurred, nearly complete defect fill resulted. However, in 16% of the collagen membrane cases and 24% of the ePTFE cases, membrane exposure was present at the time of suture removal; ultimately, 44% of the ePTFE membranes had to be removed prematurely. A staged technique using autograft and ePTFE membranes (GTAM) was described in 40 cases of horizontal ridge augmentation.<sup>47</sup> Successful application of bioabsorbable membranes in the treatment of a variety of horizontal and vertical bone defects, including implant dehiscence and fenestration type defects, has been reported.<sup>36,139,145,146</sup>

Perforation of the cortical bone layer has been advocated in GBR, because it was postulated that this increases the vascularity of the wound and releases growth factors and cells with angiogenic and

- ¶ Epi-Guide, Curasan, Research Triangle Park, NC.
- # Resolut, W.L. Gore & Associates.
- \*\* Atrisorb, Collagenex Pharmaceuticals, Newtown, PA.
- †† Guidor, Sunstar, Chicago, IL.
- ‡‡ Ossix, ColBar LifeSciences, Herzliya, Israel.
- §§ Vicryl, Johnson & Johnson Gateway, Piscataway, NJ.
- ||| Biomend, Integra LifeSciences, Plainsboro, NJ.
- ¶¶ Biomend Extend, Integra LifeSciences.
- ## CollaTape, Integra LifeSciences.
- \*\*\* CollaCote, Integra LifeSciences.
- ††† CollaPlug, Integra LifeSciences.
- ‡‡‡ RCM, Ace Surgical Supply, Brockton, MA.
- §§§ Bio-Gide, Geistlich Pharmaceutical, Wolhusen, Switzerland.
- |||| Capset, LifeCore Biomedical, Chaska, MN.
- ¶¶¶ Alloderm, LifeCell, Branchburg, NJ.
- ### Bio-Gide, Geistlich Pharmaceutical.
- \*\*\*\* CollaTape, Integra LifeSciences.
- †††† CollaPlug, Integra LifeSciences.
- ‡‡‡‡ CollaCote, LifeSciences.
- §§§§ Guidor, Sunstar.
- ||||| Bio-Gide, Geistlich Pharmaceutical.
- ¶¶¶¶ Bio-Gide, Geistlich Pharmaceutical.

osteogenic potential.<sup>123</sup> Although no evidence exists in the literature regarding a performance advantage, numerous membrane fixation products exist for improved graft containment and minimization of membrane micromotion.<sup>147</sup> Membrane micromotion was hypothesized to decrease the regenerative response by forming a layer of soft tissue under the membrane.<sup>125</sup> Products that are available to stabilize membranes include non-resorbable mini screws and tacks<sup>47,147</sup> and bioabsorbable tacks made from polylactic acid.<sup>148</sup> A pair of studies used fixation techniques as part of the experimental protocol.<sup>118,134</sup>

### **Particulate Bone Grafting Technique**

A bone graft is a tissue or material used to repair a defect or deficiency in contour and/or volume. There is a diversity of opinion regarding what particulate materials should be used for typical clinical applications, the rationale for their use, the rationale for using combinations of materials, and the percentages of each material used in combination.<sup>25,149-151</sup> Bone grafts fall into four general categories: autografts, allografts, xenografts, and alloplasts. The use of these materials in regenerative procedures is based on the assumption that they possess osteogenic potential (contain bone-forming cells), are osteoinductive (contain bone-inducing substances), or simply are osteoconductive (serve as a scaffold for bone formation). Autogenous bone harvested from intraoral or extraoral sites is the most predictable osteogenic organic graft for osseous tissue regeneration.<sup>50,61,152,153</sup>

Extraoral sites, such as the iliac crest, provide adequate quantity of graft material with excellent osteogenic, osteoinductive, and osteoconductive properties, but have a high morbidity related to the second surgical site. With the limited availability of intraoral sites, donor site morbidities, and inadequate quantity of the harvested bone, the use of other grafting materials has been advocated whenever possible.

The autograft, allograft, alloplast, and xenograft materials all have reported success, alone or in combination, for particulate bone augmentation.<sup>3</sup> The particulate autograft is the gold standard for most craniofacial bone grafting, including the treatment of dental implant-related defects.<sup>50,61,153</sup> Several studies demonstrated the effectiveness of particulate autograft.<sup>52,53,82,118</sup> However, autografts have recognized limitations, such as donor site morbidity, increased cost, potential resorption, size mismatch, and an inadequate volume of graft material.<sup>154,155</sup>

Allografts are grafts transferred between members of the same species, which are genetically dissimilar. They have the advantage of being available in higher quantities and eliminate the morbidity associated with a second surgical site. The allograft has been used

as a substitute for autografts or as an autograft expander.<sup>156</sup> Current usage primarily is in particulate form, although putty, gel, collagen sponge, sheets, and cortical and cancellous segments also are used. Biochemical extraction techniques showed that growth and differentiation factors are present in DFDBA preparations.<sup>157-160</sup> However, some reports revealed unpredictable or poor bone formation with some lots of commercially available DFDBA.<sup>159,161,162</sup> The use of particulate allograft bone replacement substitute has been reported for numerous applications, including sinus augmentation,<sup>86,163</sup> ridge augmentation,<sup>54,164</sup> and in extraction socket applications.<sup>164</sup> In a comparative study using FDBA or DFDBA for localized ridge and sinus augmentation, histologic observations showed regeneration of ~42% new bone area with no statistical difference between the two materials.<sup>37</sup> Although the risk for disease transmission essentially is non-existent, concern still exists for some patients and estimates for the risk were reported.<sup>165,166</sup> This has, in part, fueled attempts to identify alternative bone graft substitutes, such as those made from synthetic materials.

Advances in the field of biomaterials and the limitations associated with the use of autografts and allografts have directed attention toward the use of alloplastic graft materials.<sup>167</sup> These synthetic bone graft materials are osteoconductive and have no intrinsic potential for osteogenesis or induction. Osteoconduction provides for the ingrowth of capillaries, perivascular tissues, and osteoprogenitor cells from the adjacent recipient bed.<sup>168</sup> Additionally, there is no practical restriction to the available quantity of graft, and the risk for disease transmission and need for harvesting bone tissue are eliminated. They have been used successfully in dental surgical specialties in alveolar ridge preservation and augmentation<sup>169</sup> and sinus graft procedures.<sup>170,171</sup>

Bone augmentation techniques using synthetic graft materials (i.e., alloplasts) have demonstrated potential in surgical therapy for >100 years.<sup>172</sup> Calcium sulfate and calcium phosphate compounds are attractive alternatives to autografts because of their biocompatibility, handling characteristics, porosity, different rates of dissolution, chemical and physical resemblance to bone mineral, and potentially unlimited supply at a modest cost.<sup>173-177</sup> Granular porous HA has been considered a unique alloplast, in that it is formed by the hydrothermal chemical conversion of sea coral from biogenic carbonate to HA.<sup>178</sup> Ridge augmentation with HA particulate, with and without autogenous bone or plaster, was reported.<sup>179</sup> Sinus augmentation with HA showed success and excellent dimensional stability.<sup>67,85,87</sup> The second generation of calcium phosphate bone cements has shown promise in orthopedic and

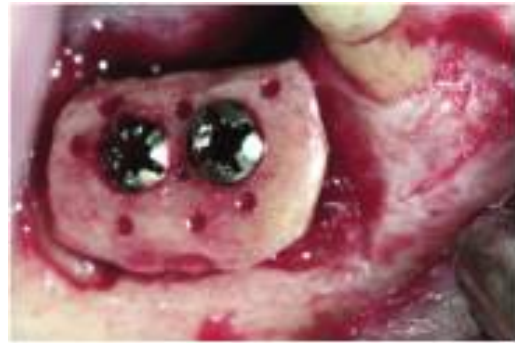

maxillofacial reconstruction, which also could indicate a use in implant reconstruction.<sup>176</sup>

The use of xenografts for bone grafting was reported in 1889.<sup>180</sup> Xenografts are derived from another species and are considered to be biocompatible and osteoconductive. Bovine-derived particulate preparations that have the organic components removed demonstrated successful bone regeneration in numerous human bone augmentation studies.<sup>51,86,163,181</sup> Many of these xenograft materials have the potential to resorb and be replaced with host bone over time.<sup>100,181,182</sup> Although having limited evaluation in bone augmentation application, the percentage area of bone fill in a bilateral sinus augmentation case report that compared a mixture of a xenograft ##### plus autogenous bone to the same xenograft containing the collagen cell-binding domain peptide P-15\*\*\*\*\* alone was reported.<sup>183</sup> (The peptide component, P-15, is a synthetic clone of the 15 amino acid sequence of type I collagen that is involved uniquely in the binding of connective tissue cells.<sup>184</sup>) The investigators reported that at 4 months, histomorphometric analysis revealed that the peptide component–treated side had similar quantity of bone to the xenograft/autogenous bone–grafted side of 8 months, suggesting an accelerated bone fill in the presence of the P-15 component.<sup>183</sup> Because the observations were based on one case, the validity of the treatment concept cannot be forecast adequately from such a small sample size. The use of the peptide component alone<sup>185</sup> and in combination with autogenous bone or another xenograft<sup>186</sup> was reported in other sinus augmentation applications. Although the amount of new bone formation achieved among the various biomaterials used did not show statistical significance, and the use of the peptide component has been advocated as a suitable substitute for autogenous bone, the lack of a true control in the study design makes extrapolation of findings difficult clinically. Further controlled studies are warranted to assess the value of these xenografts in ridge augmentation application.

### Block Grafting Approaches

When using autogenous block graft approaches for bone augmentation, a considerable amount of horizontal augmentation can be added predictably to the defect area.<sup>47,187-189</sup> A recent study on 115 autogenous block grafts reported only one complete failure where the block graft was removed.<sup>189</sup> The stabilization and intimate contact of these block grafts to the recipient bed has been considered crucial to a successful outcome.<sup>190,191</sup> This can be achieved with the use of bone fixation screws<sup>47,192</sup> (Fig. 3) or the simultaneous placement of dental implants<sup>113,193-195</sup> Aggressive recipient bed preparation with decortication, intramarrow penetration, and inlay shaping also



**Figure 3.**

A block graft, harvested from the ramus, secured with fixation screws. Note perforations within the block graft and the recipient bed (not shown) allowing for an increase in the rate of revascularization, the availability of osteoprogenitor cells, and the increased rate of remodeling.

has been supported, because of increases in the rate of revascularization, the availability of osteoprogenitor cells, and the increased rate of remodeling.<sup>163,189,190,196-198</sup> The healing of autogenous block grafts has been described as “creeping substitution” where viable bone replaces the necrotic bone within the graft<sup>199</sup> and is highly dependent on graft angiogenesis and revascularization. A variety of autologous onlay bone graft techniques has been used for the entire severely resorbed edentulous maxilla and mandible.<sup>193,200,201</sup> Although results have improved from the initially reported 50% failure rates,<sup>193</sup> graft resorption, complications, and implant survival rates are still a concern for these full-arch grafting procedures.<sup>58,202</sup>

The primary locations for harvesting intraoral block grafts include the external oblique ridge of the posterior mandible, symphysis, and ramus.<sup>50,187,203</sup> With bone defects >2 cm, an extraoral autogenous bone harvest from the iliac crest, cranium, or tibia is used often.<sup>50</sup> In addition to the ease of intraoral harvest, grafts derived from intramembranous bone have less resorption than endochondral bone.<sup>204</sup> Resorption rates of 0% to 25%<sup>58,205,206</sup> at the time of implant placement and up to 60%<sup>207</sup> at abutment connection were documented with the use of autogenous block grafts. With regard to graft resorption, an optimized outcome for ridge augmentation with block grafts is achieved with barrier membranes.<sup>47,208,209</sup> A recent human study showed a 17% resorption of mandibular block grafts used in combination with particulate autograft and xenograft for vertical ridge augmentation, with an average gain of ~5 mm.<sup>58</sup> This study also demonstrated retained vitality of the block autografts. Block grafts are harvested as corticocancellous or

##### OsteoGraf/N, Dentsply/Friadent/CeraMed, Lakewood, CO.  
\*\*\*\*\* PepGen P-15, CeraMed.



cortical bone autografts. The revascularization of corticocancellous block grafts takes place at a much faster rate than in cortical bone autografts<sup>210</sup> and at a slower rate than particulate autografts.<sup>211</sup> Revascularization of block grafts enables maintenance of their vitality, and, hence, reduces chances of graft infection and necrosis. Many studies demonstrated maintenance of intramembranous block graft vitality.<sup>192,212,213</sup>

Although autogenous bone grafts (as block or particulate form) remain the gold standard for ridge augmentation, donor site morbidity associated with block graft harvest has turned attention to the use of allogenic block graft materials (Fig. 4). Case reports demonstrated success with FDBA and DFDBA block graft material for application in horizontal ridge augmentation procedures.<sup>214-216</sup> However, further comparative studies are warranted to evaluate the healing of these allogenic blocks histologically.

#### Combination Approaches

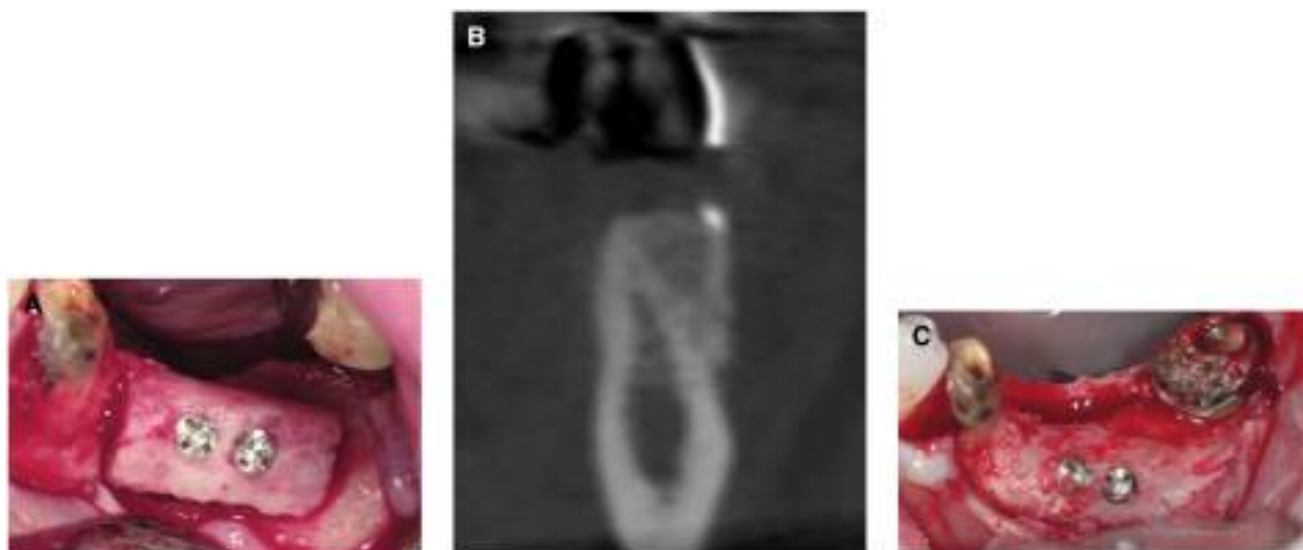
With reference to GBR techniques and based on the aforementioned observations, it is assumed that grafting of large bone defects may be advantageous to preserve the present bone tissue and increase the volume of regenerated bone. The use of graft material in non-space-making bone defects also provides for additional membrane support and prevents their collapse and occlusion of the space into which bone regeneration is anticipated. Membranes may be used in combination with block grafts and/or particulate graft materials to maximize the regenerative outcome (Fig. 5).<sup>49,53,217,218</sup> This combination approach can

be used for more involved defects than those applicable for the individual approaches alone.<sup>218,219</sup> Without underlying graft materials or reinforcement with the use of tenting screws,<sup>220</sup> barrier membranes may be compressed into the space of the bony defect by the overlying soft tissue during healing.<sup>27,49,123,221</sup> In many situations, a membrane may not be required, and the graft material alone can be effective.<sup>219</sup> In some reports,<sup>192,222</sup> resorption was reported with autografts when no membrane was used. In one report,<sup>222</sup> 0.9 mm of the 3.6-mm grafted width increase was lost to resorption when the maxillary tuberosity was used, which may be a function of the type of donor bone. In another study,<sup>209</sup> significantly less resorption of the block grafts was found when ePTFE membranes were used to protect the graft. A histologic study<sup>52</sup> that used autograft and barrier membranes in humans revealed a bone-implant contact of 22% in the 4 mm of vertically regenerated bone, compared to the 44% found in native bone. A 5-year analysis<sup>112</sup> of the vertical augmentation with this approach demonstrated stable vertical gains.

Combination approaches may be applied to implant placement where the grafting procedure is performed at the time of implant surgery. This reduces the healing period and decreases the number of surgeries required and the morbidity and cost to the patient.

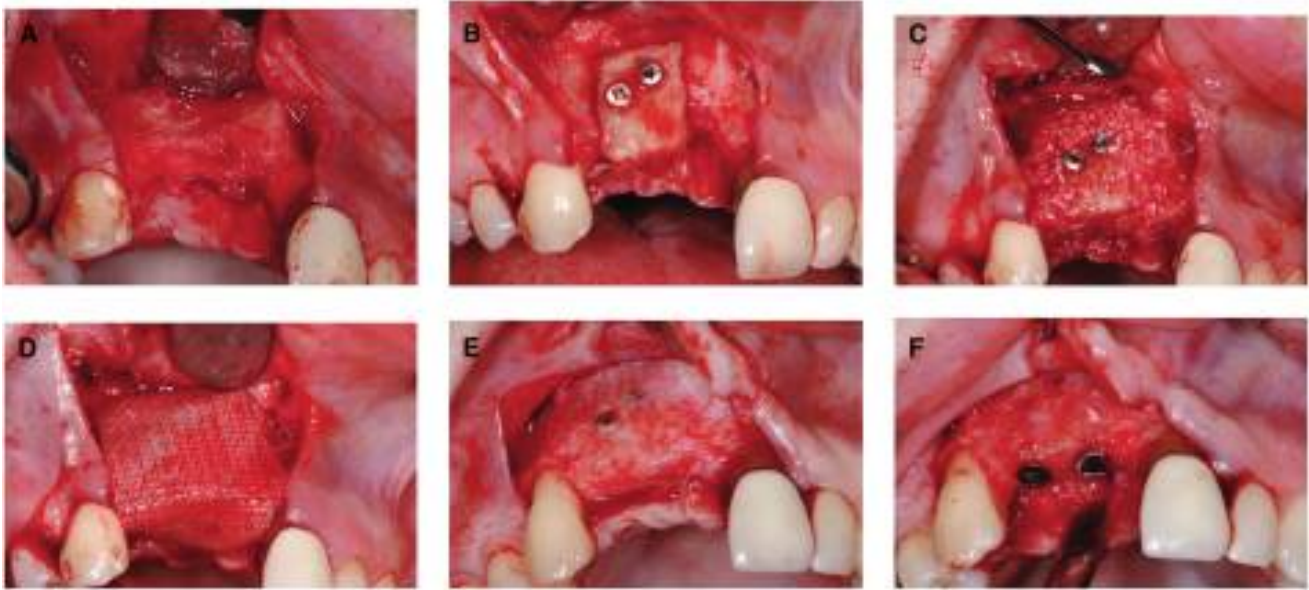
#### Ridge Expansion Techniques

Ridge splitting is an alternative to the various techniques described for horizontal ridge augmentation, including distraction osteogenesis (described later);



**Figure 4.**

**A)** Proper adaptation and stabilization of the allogenic block graft within the recipient site, ensuring good vascularity from the host bone. **B)** Cone-beam computed tomography image of graft at 6 months of healing showing excellent ridge width for implant placement. **C)** Six months postoperative view of the allogenic graft showing good maintenance of its bucco-lingual dimension.

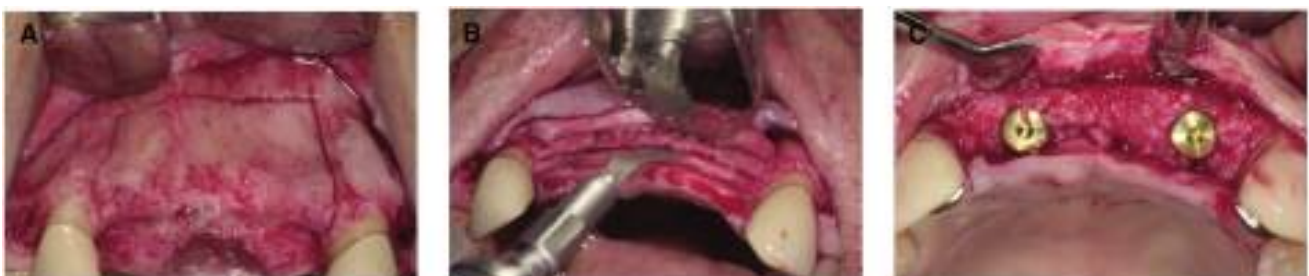

### Figure 5.

**A)** Vertical and horizontal ridge defect at 3 months following extraction of traumatized teeth #7 and #8. **B)** Adaptation and stabilization of a symphyseal autologous block graft. **C)** Placement of a combination of particulate xenograft and autologous bone graft to achieve fill of the defect. **D)** Placement of a collagen membrane over the grafted defect. **E)** Six months postoperative view of the reconstructed ridge. **F)** Implant placement revealed a stable reconstructed ridge.

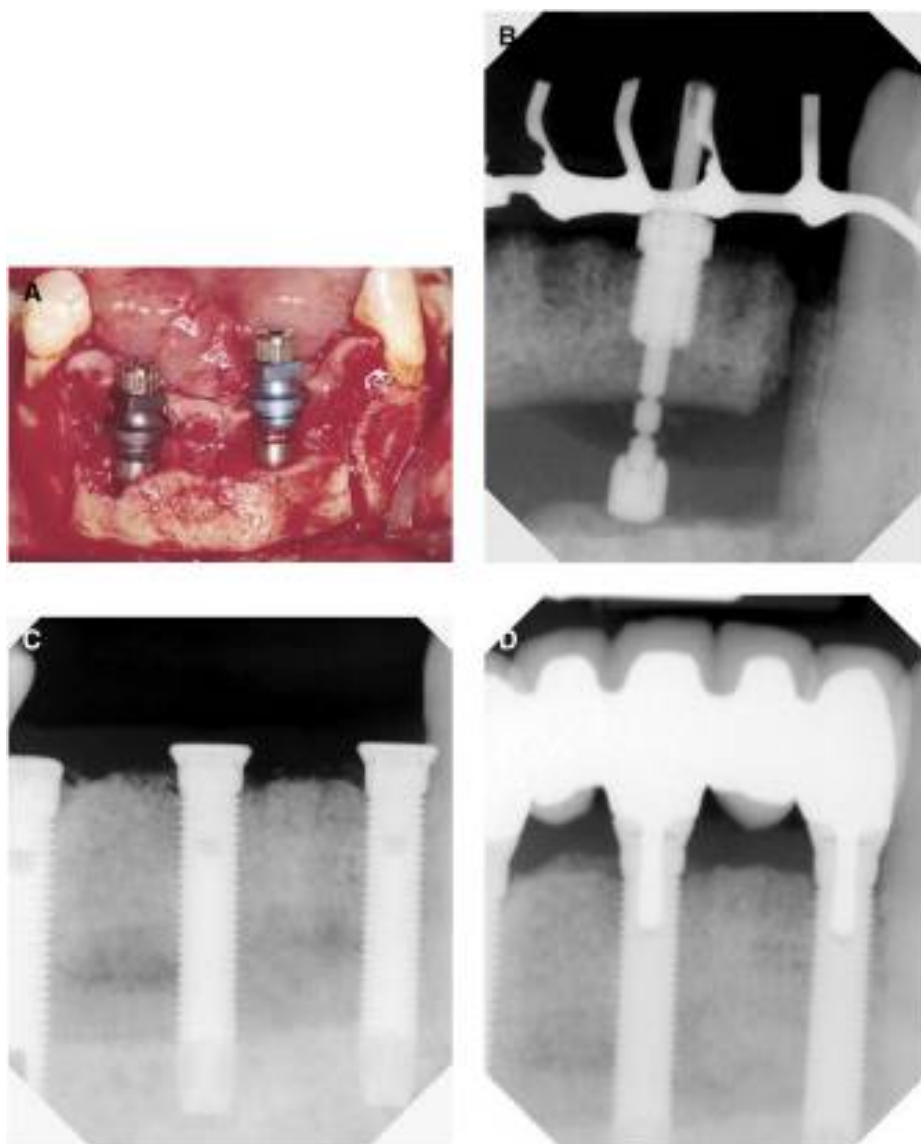
it has a similar healing pattern and end result.<sup>223,224</sup> With a narrow ridge, splitting the alveolar bone longitudinally, using chisels, osteotomes, or piezosurgical devices,<sup>225</sup> can be performed to increase the horizontal ridge width, provided the buccal and lingual cortical plates are not fused and some intervening cancellous bone is present. With adequate vascularity and stabilization of the mobile bone segment, together with sufficient interpositional bone grafting and soft tissue protection, a comparable result to alternate techniques can be obtained.<sup>223,224</sup> A 5-year study<sup>226</sup> evaluating 449 implants placed in maxillary ridges expanded by the ridge split technique revealed a survival rate of 97%, which is consistent with placement in native bone. Recently, a modified two-phase approach

to the ridge split technique was introduced that aims at minimizing the risk for unfavorable fractures of the segment in less flexible bone, as well as maintaining the segment vascularity during its expansion (Fig. 6). In the first surgery, a full-thickness mucoperiosteal flap is elevated on the buccal aspect of the ridge. A saw, bur, or piezosurgical device is used to perform the apical horizontal and proximal and distal vertical corticotomies. The crestal corticotomy can be made at the primary or secondary operation. The second surgery, a month later, involves the splitting and expansion of the ridge using osteotomes. At this stage, split-thickness buccal mucoperiosteal flap is elevated to preserve the vascularity of the buccal cortical plate. Implants can be placed in the space created between



### Figure 6.

**A)** A staged ridge-expansion technique. Vertical and horizontal corticotomies are made at stage one. **B)** After 1 month at stage two and following a partial-thickness flap elevation, a conventional ridge-expansion is performed. A sagittal saw is used to perform the crestal corticotomy. **C)** Implants at their uncoveries 6 months following their simultaneous placement at the time of the ridge-expansion procedure.



#### Figure 7.

**A)** Application of two intraosseous distractors at time of site preparation for correction of a 7-mm mandibular anterior vertical defect. **B)** Radiographic view of an intraosseous distractor following distraction of the segment. Note that the bone segment is distracted beyond the desired level to allow for some vertical resorption typically observed during healing of the distracted segment. **C** and **D)** Gradual consolidation of the distracted osseous segment with good bone height maintenance around the loaded implants 3 years postoperatively.

the buccal and lingual plates, with or without interpositional grafting.<sup>223,227,228</sup> The primary advantages of the ridge split technique using particulate, block graft, or GBR, compared to the mentioned lateral augmentation techniques, are reduced treatment time and reduced morbidity resulting from avoiding a separate donor site.

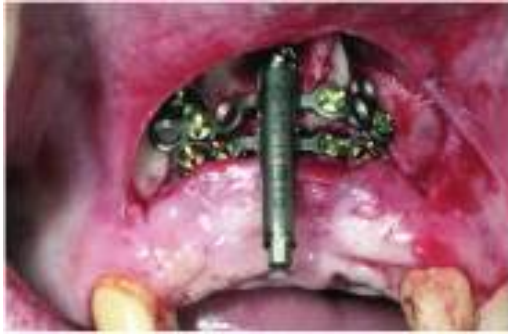#### Distraction Osteogenesis

Distraction osteogenesis uses the long-standing biologic phenomenon that new bone fills in the gap defect

created when two pieces of bone are separated slowly under tension.<sup>229-233</sup> Distraction of the segment can be achieved in a vertical and/or a horizontal direction.<sup>234</sup> The basic principles involved in distraction osteogenesis include a latency period of 7 days for initial post-surgical soft tissue wound healing, a distraction phase during which the two pieces of bone undergo gradual incremental separation at a rate of ~1 mm per day, and a consolidation phase that allows bone regeneration in the created space.<sup>231,235,236</sup> A number of case reports demonstrated the potential for successful results with a variety of alveolar bone distractors.<sup>60,237-240</sup> Distractor devices are of an intraosseous (Fig. 7) or extraosseous configuration (Fig. 8). When the clinical requirement for significant vertical ridge augmentation exists, distraction osteogenesis can be used successfully with a variety of devices.<sup>241</sup> Thorough assessment and treatment planning is imperative for success. The prerequisites for optimal bone augmentation of defects using distraction osteogenesis are a minimum of 6 to 7 mm of bone height above vital structures, such as neurovascular bundles or air passages/sinus cavities, a vertical ridge defect of  $\geq 3$  to 4 mm, and an edentulous ridge span of three or more missing teeth. The height of bone on adjacent teeth acts as reference points

for the extent of vertical gain that can be achieved. Improvement of attachment levels on teeth with distraction has not been successful in the animal model.<sup>242</sup> Therefore, compromised dentition with considerable bone loss may need to be extracted to create a true vertical component of 4 mm within the defect span. Smaller ridge defects of one or two teeth in width were associated with higher rates of complications when treated with the distraction technique.<sup>243</sup> In such cases, conventional ridge augmentation techniques should be used.<sup>56,58,244</sup> An intraosseous dental





**Figure 8.**

*An extraosseous distractor at placement.*

implant-like distractor that was evaluated in dogs showed vertical gains of up to 9 mm in human case reports.<sup>60,239</sup> Another device, with a small-diameter intraosseous approach, was used successfully for 9 mm of vertical movement prior to implant placement.<sup>59</sup> In contrast to these internal designs, an extraosseous distraction system with all moving components external to the cortical plate was developed and used successfully.<sup>240,245</sup> The use of a prosthetic restorable distractor also was described showing a 4- to 6-mm increase in vertical height.<sup>238</sup> Data on implant success in distracted bone out 3 to 5 years showed favorable results comparable to other grafting approaches.<sup>243</sup>

### FUTURE BONE AUGMENTATION APPROACHES

Future bone augmentation approaches likely will use molecular, cellular, and genetic tissue engineering technologies.<sup>246</sup> Numerous studies<sup>13,247-250</sup> evaluated these approaches; however, they have not received U.S. Food and Drug Administration (FDA) approval for bone augmentation use for dental implant reconstruction. The molecular approach using BMPs has received the most attention over the past decade. BMPs are differentiation factors that are part of the transforming growth factor superfamily.<sup>176</sup> They have multiple effects, including the ability to differentiate osteoprogenitor cells into mineral-forming osteoblasts.<sup>5</sup> Two of these proteins, BMP-2 and -7 (or osteogenic protein-1), have been cloned, studied extensively, and show promise for intraoral applications.<sup>251,252</sup> Human studies<sup>13,247</sup> demonstrated product safety with BMP-2 in ridge preservation and sinus augmentation applications. Although BMP-2 has been approved by the FDA for spinal fusion application, for human intraoral applications the carriers and dosage of BMP-2 and -7 are still under regulatory review and investigation. Although a large number of growth factors is being evaluated actively, platelet-derived growth factor (PDGF) has received the most

attention for intraoral use.<sup>250</sup> When the combination use of PDGF with ePTFE membranes around immediate implants was evaluated in dogs, PDGF with insulin growth factor showed more rapid bone formation than the negative control that included the carrier alone.<sup>250</sup> In another recent dog study<sup>253</sup> evaluating recombinant human PDGF-BB (rhPDGF-BB) and inorganic bone blocks for vertical bone augmentation application, test sites with rhPDGF-BB showed statistically significantly more vertical bone growth than controls. Recently, rh-PDGF combined with a tri-calcium phosphate (TCP) carrier at a concentration of 0.3 mg/ml was approved for periodontal regeneration.<sup>254</sup> As with the differentiation factors, the optimal carriers and growth factor dosages are still under investigation and regulatory review for intraoral bone augmentation use. The binding kinetics for growth and differentiation factors are substrate specific; therefore, to optimize the clinical outcome with different carriers, full binding and release evaluations need to be completed along with animal and human dosing studies.

Another growth factor approach is to use the patient's own blood, separating out the platelet-rich plasma (PRP) and adding this concentrated group of autogenous growth factors to the grafting material.<sup>255</sup> The addition of PRP to autogenous grafts showed a more rapid and dense bone formation compared to autogenous grafts used alone for bone augmentation.<sup>255</sup> An improvement in bone formation when PRP is added to other graft materials has not been demonstrated clearly.<sup>68,256</sup>

Gene therapy is a relatively new therapeutic modality based on the potential for delivery of altered genetic material to the cell.<sup>257</sup> Localized gene therapy can be used to increase the concentration of desired growth or differentiation factors to enhance the regenerative response.<sup>258</sup> With the current requirement for supraphysiologic BMP doses to obtain acceptable clinical results, this approach to deliver higher concentrations to the local bone augmentation site over longer periods of time shows promise.<sup>249,259</sup>

A cellular tissue engineering strategy that exploits the regenerative capacity of bone may include the *in vitro* amplification of osteoblast cells or osteoprogenitor cells grown within three-dimensional constructs.<sup>260-262</sup> Approaches specifically targeting intraoral bone augmentation demonstrated *in vitro* osteoblast amplification in different constructs.<sup>262-264</sup> Alternatively, the use of mesenchymal stem cells for construct seeding<sup>265,266</sup> or development of an immortalized osteoblast line showed promise for bone regeneration.<sup>267</sup> These amplification approaches, in combination with gene therapy and molecular stimulation, may lead to improved approaches for multifactorial tissue engineering strategies aimed at alveolar bone augmentation.<sup>258</sup>



## CONCLUSIONS

Many techniques exist for effective bone augmentation. The approach largely is dependent on the extent of the defect and specific procedures to be performed for the implant reconstruction. It is most appropriate to use an evidenced-based approach when a treatment plan is being developed for bone augmentation cases.

## REFERENCES

- Brighton C, Friedlaender G, Lane J. *Bone Formation and Repair*. Rosemont, IL: American Academy of Orthopedic Surgeons; 1994:542.
- Serletti J, Manson P, Leipziger L. Trauma surgery. In: Reddi AH, Habal M, eds. *Bone Grafts and Bone Substitutes*. Philadelphia: W.B. Saunders; 1992:419.
- Hollinger JO, Brekke J, Gruskin E, Lee D. Role of bone substitutes. *Clin Orthop* 1996;Mar(324):55-65.
- Aukhil I, Simpson DM, Suggs C, Pettersson E. In vivo differentiation of progenitor cells of the periodontal ligament. An experimental study using physical barriers. *J Clin Periodontol* 1986;13:862-868.
- Urist MR. Bone: Formation by autoinduction. *Science* 1965;150:893-899.
- Tarnow DP, Eskow RN, Zamzok J. Aesthetics and implant dentistry. *Periodontol 2000* 1996;11:85-94.
- American Academy of Periodontology. *Glossary of Periodontol Terms*, 4th ed. Chicago: American Academy of Periodontology; 2001:44.
- Nevins M, Mellonig JT, Clem DS III, et al. Implants in regenerated bone: Long-term survival. *Int J Periodontics Restorative Dent* 1998;18:34-45.
- Seibert JS. Reconstruction of deformed, partially edentulous ridges, using full thickness onlay grafts. Part I. Technique and wound healing. *Compend Contin Educ Dent* 1983;4:437-453.
- Allen EP, Gainza CS, Farthing GG, Newbold DA. Improved technique for localized ridge augmentation. A report of 21 cases. *J Periodontol* 1985;56:195-199.
- Pietrokovski J, Massler M. Alveolar ridge resorption following tooth extraction. *J Prosthet Dent* 1967;17:21-27.
- Camargo PM, Lekovic V, Weinlaender M, et al. Influence of bioactive glass on changes in alveolar process dimensions after exodontia. *Oral Surg Oral Med Oral Pathol Oral Radiol Endod* 2000;90:581-586.
- Fiorellini JP, Howell TH, Cochran D, et al. Randomized study evaluating recombinant human bone morphogenetic protein-2 for extraction socket augmentation. *J Periodontol* 2005;76:605-613.
- Zubillaga G, Von Hagen S, Simon BI, Deasy MJ. Changes in alveolar bone height and width following post-extraction ridge augmentation using a fixed bioabsorbable membrane and demineralized freeze-dried bone osteoinductive graft. *J Periodontol* 2003;74:965-975.
- Becker W, Dahlin C, Becker BE, et al. The use of e-PTFE barrier membranes for bone promotion around titanium implants placed into extraction sockets: A prospective multicenter study. *Int J Oral Maxillofac Implants* 1994;9:31-40.
- Brugnami F, Then PR, Moroi H, Leone CW. Histologic evaluation of human extraction sockets treated with demineralized freeze-dried bone allograft (DFDBA) and cell occlusive membrane. *J Periodontol* 1996;67:821-825.
- Lekovic V, Camargo PM, Klokkevold PR, et al. Preservation of alveolar bone in extraction sockets using bioabsorbable membranes. *J Periodontol* 1998;69:1044-1049.
- Lekovic V, Kenney EB, Weinlaender M, et al. A bone regenerative approach to alveolar ridge maintenance following tooth extraction. Report of 10 cases. *J Periodontol* 1997;68:563-570.
- Vance GS, Greenwell H, Miller RL, et al. Comparison of an allograft in an experimental putty carrier and a bovine-derived xenograft used in ridge preservation: A clinical and histologic study in humans. *Int J Oral Maxillofac Implants* 2004;19:491-497.
- Lasella JM, Greenwell H, Miller RL, et al. Ridge preservation with freeze-dried bone allograft and a collagen membrane compared to extraction alone for implant site development: A clinical and histologic study in humans. *J Periodontol* 2003;74:990-999.
- Nevins M, Camelo M, De Paoli S, et al. A study of the fate of the buccal wall of extraction sockets of teeth with prominent roots. *Int J Periodontics Restorative Dent* 2006;26:19-29.
- Amler MH, Johnson PL, Salman I. Histological and histochemical investigation of human alveolar socket healing in undisturbed extraction wounds. *J Am Dent Assoc* 1960;61:32-44.
- Boyne PJ. Osseous repair of the postextraction alveolus in man. *Oral Surg Oral Med Oral Pathol* 1966;21:805-813.
- Ohta Y. Comparative changes in microvasculature and bone during healing of implant and extraction sites. *J Oral Implantol* 1993;19:184-198.
- Becker W, Becker BE, Caffesse R. A comparison of demineralized freeze-dried bone and autologous bone to induce bone formation in human extraction sockets. *J Periodontol* 1994;65:1128-1133.
- Becker W, Clokie C, Sennerby L, et al. Histologic findings after implantation and evaluation of different grafting materials and titanium micro screws into extraction sockets: Case reports. *J Periodontol* 1998;69:414-421.
- Hurzeler MB, Kohal RJ, Naghshbandi J, et al. Evaluation of a new bioresorbable barrier to facilitate guided bone regeneration around exposed implant threads. An experimental study in the monkey. *Int J Oral Maxillofac Surg* 1998;27:315-320.
- Okamoto T, Onofre Da Silva A. Histological study on the healing of rat dental sockets after partial removal of the buccal bony plate. *J Nihon Univ Sch Dent* 1983;25:202-213.
- Simpson HE. Experimental investigation into the healing of extraction wounds in macacus rhesus monkeys. *J Oral Surg Anesth Hosp Dent Serv* 1960;18:391-399.
- Sclar AG. Strategies for management of single-tooth extraction sites in aesthetic implant therapy. *J Oral Maxillofac Surg* 2004;62(Suppl. 2):90-105.
- Gelb DA. Immediate implant surgery: Three-year retrospective evaluation of 50 consecutive cases. *Int J Oral Maxillofac Implants* 1993;8:388-399.
- Lazzara RJ. Immediate implant placement into extraction sites: Surgical and restorative advantages. *Int J Periodontics Restorative Dent* 1989;9:332-343.
- Dahlin C, Lekholm U, Lindhe A. Membrane-induced bone augmentation at titanium implants. A report on ten fixtures followed from 1 to 3 years after loading. *Int J Periodontics Restorative Dent* 1991;11:273-281.

34. Schropp L, Kostopoulos L, Wenzel A. Bone healing following immediate versus delayed placement of titanium implants into extraction sockets: A prospective clinical study. *Int J Oral Maxillofac Implants* 2003;18:189-199.
35. Augthun M, Yildirim M, Spiekermann H, Biesterfeld S. Healing of bone defects in combination with immediate implants using the membrane technique. *Int J Oral Maxillofac Implants* 1995;10:421-428.
36. Simion M, Misitano U, Gionso L, Salvato A. Treatment of dehiscences and fenestrations around dental implants using resorbable and nonresorbable membranes associated with bone autografts: A comparative clinical study. *Int J Oral Maxillofac Implants* 1997;12:159-167.
37. Cammack GV II, Nevins M, Clem DS III, et al. Histologic evaluation of mineralized and demineralized freeze-dried bone allograft for ridge and sinus augmentations. *Int J Periodontics Restorative Dent* 2005;25:231-237.
38. Block MS, Kent JN. Placement of endosseous implants into tooth extraction sites. *J Oral Maxillofac Surg* 1991;49:1269-1276.
39. Paolantonio M, Dolci M, Scarano A, et al. Immediate implantation in fresh extraction sockets. A controlled clinical and histological study in man. *J Periodontol* 2001;72:1560-1571.
40. Ashman A. An immediate tooth root replacement: An implant cylinder and synthetic bone combination. *J Oral Implantol* 1990;16:28-38.
41. Edel A. The use of a connective tissue graft for closure over an immediate implant covered with occlusive membrane. *Clin Oral Implants Res* 1995;6:60-65.
42. Evian CI, Cutler S. Autogenous gingival grafts as epithelial barriers for immediate implants: Case reports. *J Periodontol* 1994;65:201-210.
43. Yukna RA. Clinical comparison of hydroxyapatite-coated titanium dental implants placed in fresh extraction sockets and healed sites. *J Periodontol* 1991;62:468-472.
44. Botticelli D, Berglundh T, Buser D, Lindhe J. The jumping distance revisited: An experimental study in the dog. *Clin Oral Implants Res* 2003;14:35-42.
45. Wilson TG Jr., Schenk R, Buser D, Cochran D. Implants placed in immediate extraction sites: A report of histologic and histometric analyses of human biopsies. *Int J Oral Maxillofac Implants* 1998;13:333-341.
46. Rosenquist B, Grenthe B. Immediate placement of implants into extraction sockets: Implant survival. *Int J Oral Maxillofac Implants* 1996;11:205-209.
47. Buser D, Dula K, Hirt HP, Schenk RK. Lateral ridge augmentation using autografts and barrier membranes: A clinical study with 40 partially edentulous patients. *J Oral Maxillofac Surg* 1996;54:420-432.
48. Dahlin C, Lekholm U, Becker W, et al. Treatment of fenestration and dehiscence bone defects around oral implants using the guided tissue regeneration technique: A prospective multicenter study. *Int J Oral Maxillofac Implants* 1995;10:312-318.
49. Mellonig JT, Nevins M. Guided bone regeneration of bone defects associated with implants: An evidence-based outcome assessment. *Int J Periodontics Restorative Dent* 1995;15:168-185.
50. Tolman DE. Reconstructive procedures with endosseous implants in grafted bone: A review of the literature. *Int J Oral Maxillofac Implants* 1995;10:275-294.
51. Zitzmann NU, Naef R, Scharer P. Resorbable versus nonresorbable membranes in combination with Bio-Oss for guided bone regeneration. *Int J Oral Maxillofac Implants* 1997;12:844-852.
52. Parma-Benfenati S, Tinti C, Albrektsson T, et al. Histologic evaluation of guided vertical ridge augmentation around implants in humans. *Int J Periodontics Restorative Dent* 1999;19:424-437.
53. Simion M, Jovanovic SA, Trisi P, et al. Vertical ridge augmentation around dental implants using a membrane technique and autogenous bone or allografts in humans. *Int J Periodontics Restorative Dent* 1998;18:8-23.
54. Simion M, Trisi P, Piattelli A. Vertical ridge augmentation using a membrane technique associated with osseointegrated implants. *Int J Periodontics Restorative Dent* 1994;14:496-511.
55. Tinti C, Parma-Benfenati S, Polizzi G. Vertical ridge augmentation: What is the limit? *Int J Periodontics Restorative Dent* 1996;16:220-229.
56. Proussaefs P, Lozada J, Kleinman A, et al. The use of titanium mesh in conjunction with autogenous bone graft and inorganic bovine bone mineral (Bio-Oss) for localized alveolar ridge augmentation: A human study. *Int J Periodontics Restorative Dent* 2003;23:185-195.
57. Salama H, Salama M. The role of orthodontic extrusive remodeling in the enhancement of soft and hard tissue profiles prior to implant placement: A systematic approach to the management of extraction site defects. *Int J Periodontics Restorative Dent* 1993;13:312-333.
58. Proussaefs P, Lozada J. The use of intraorally harvested autogenous block grafts for vertical alveolar ridge augmentation: A human study. *Int J Periodontics Restorative Dent* 2005;25:351-363.
59. Chin M, Toth BA. Distraction osteogenesis in maxillofacial surgery using internal devices: Review of five cases. *J Oral Maxillofac Surg* 1996;54:45-53.
60. Urbani G, Lombardo G, Santi E, et al. Distraction osteogenesis to achieve mandibular vertical bone regeneration: A case report. *Int J Periodontics Restorative Dent* 1999;19:321-331.
61. Lundgren S, Moy P, Johansson C, et al. Augmentation of the maxillary sinus floor with particulated mandible: A histologic and histomorphometric study. *Int J Oral Maxillofac Implants* 1996;11:760-766.
62. Truhlar RS, Orenstein IH, Morris HF, et al. Distribution of bone quality in patients receiving endosseous dental implants. *J Oral Maxillofac Surg* 1997;55:38-45.
63. Boyne PJ, James RA. Grafting of the maxillary sinus floor with autogenous marrow and bone. *J Oral Surg* 1980;38:613-616.
64. Smiler DG, Johnson PW, Lozada JL, et al. Sinus lift grafts and endosseous implants. Treatment of the atrophic posterior maxilla. *Dent Clin North Am* 1992;36:151-186.
65. Tatum H Jr. Maxillary and sinus implant reconstructions. *Dent Clin North Am* 1986;30:207-229.
66. Lazzara RJ. The sinus elevation procedure in endosseous implant therapy. *Curr Opin Periodontol* 1996;3:178-183.
67. Jensen OT, Shulman LB, Block MS, Iacono VJ. Report of the Sinus Consensus Conference of 1996. *Int J Oral Maxillofac Implants* 1998;13(Suppl.):11-45.
68. Wallace SS, Froum SJ. Effect of maxillary sinus augmentation on the survival of endosseous dental

- implants. A systematic review. *Ann Periodontol* 2003; 8:328-343.
69. Simion M, Fontana F, Rasperini G, et al. Long-term evaluation of osseointegrated implants placed in sites augmented with sinus floor elevation associated with vertical ridge augmentation: A retrospective study of 38 consecutive implants with 1- to 7-year follow-up. *Int J Periodontics Restorative Dent* 2004;24:208-221.
  70. Summers RB. A new concept in maxillary implant surgery: The osteotome technique. *Compendium* 1994;15:152, 154-156, 158 passim; quiz 162.
  71. Fugazzotto PA. Sinus floor augmentation at the time of maxillary molar extraction: Technique and report of preliminary results. *Int J Oral Maxillofac Implants* 1999; 14:536-542.
  72. Summers RB. The osteotome technique: Part 3 – Less invasive methods of elevating the sinus floor. *Compendium* 1994;15:698, 700, 702-694 passim; quiz 710.
  73. Bragger U, Gerber C, Joss A, et al. Patterns of tissue remodeling after placement of ITI dental implants using an osteotome technique: A longitudinal radiographic case cohort study. *Clin Oral Implants Res* 2004;15:158-166.
  74. Fugazzotto PA, de Paoli S. Sinus floor augmentation at the time of maxillary molar extraction: Success and failure rates of 137 implants in function for up to three years. *J Periodontol* 2002;24:177-183.
  75. Zitzmann NU, Scharer P. Sinus elevation procedures in the resorbed posterior maxilla. Comparison of the crestal and lateral approaches. *Oral Surg Oral Med Oral Pathol Oral Radiol Endod* 1998;85:8-17.
  76. Rosen PS, Summers R, Mellado JR, et al. The bone-added osteotome sinus floor elevation technique: Multi-center retrospective report of consecutively treated patients. *Int J Oral Maxillofac Implants* 1999;14:853-858.
  77. Wallace SS. Lateral window sinus augmentation using bone replacement grafts: A biologically sound surgical technique. *Alpha Omega* 2005;98:36-46.
  78. Fugazzotto PA, Vlassis J. Long-term success of sinus augmentation using various surgical approaches and grafting materials. *Int J Oral Maxillofac Implants* 1998; 13:52-58.
  79. Cordioli G, Mazzocco C, Schepers E, et al. Maxillary sinus floor augmentation using bioactive glass granules and autogenous bone with simultaneous implant placement. Clinical and histological findings. *Clin Oral Implants Res* 2001;12:270-278.
  80. Daelemans P, Hermans M, Godet F, et al. Autologous bone graft to augment the maxillary sinus in conjunction with immediate endosseous implants: A retrospective study up to 5 years. *Int J Periodontics Restorative Dent* 1997;17:27-39.
  81. Froum SJ, Tarnow DP, Wallace SS, et al. Sinus floor elevation using anorganic bovine bone matrix (OsseoGraf/N) with and without autogenous bone: A clinical, histologic, radiographic, and histomorphometric analysis – Part 2 of an ongoing prospective study. *Int J Periodontics Restorative Dent* 1998;18:528-543.
  82. Wood RM, Moore DL. Grafting of the maxillary sinus with intraorally harvested autogenous bone prior to implant placement. *Int J Oral Maxillofac Implants* 1988; 3:209-214.
  83. Chanavaz M. Maxillary sinus: Anatomy, physiology, surgery, and bone grafting related to implantology – Eleven years of surgical experience (1979-1990). *J Oral Implantol* 1990;16:199-209.
  84. Chanavaz M. Sinus grafting related to implantology. Statistical analysis of 15 years of surgical experience (1979-1994). *J Oral Implantol* 1996;22:119-130.
  85. Hurzeler MB, Kirsch A, Ackermann KL, et al. Reconstruction of the severely resorbed maxilla with dental implants in the augmented maxillary sinus: A 5-year clinical investigation. *Int J Oral Maxillofac Implants* 1996;11:466-475.
  86. Valentini P, Abensur D. Maxillary sinus floor elevation for implant placement with demineralized freeze-dried bone and bovine bone (Bio-Oss): A clinical study of 20 patients. *Int J Periodontics Restorative Dent* 1997; 17:232-241.
  87. Small SA, Zinner ID, Panno FV, et al. Augmenting the maxillary sinus for implants: Report of 27 patients. *Int J Oral Maxillofac Implants* 1993;8:523-528.
  88. Wannfors K, Johansson B, Hallman M, et al. A prospective randomized study of 1- and 2-stage sinus inlay bone grafts: 1-year follow-up. *Int J Oral Maxillofac Implants* 2000;15:625-632.
  89. Boyne PJ, Marx RE, Nevins M, et al. A feasibility study evaluating rhBMP-2/absorbable collagen sponge for maxillary sinus floor augmentation. *Int J Periodontics Restorative Dent* 1997;17:11-25.
  90. Avera SP, Stampley WA, McAllister BS. Histologic and clinical observations of resorbable and nonresorbable barrier membranes used in maxillary sinus graft containment. *Int J Oral Maxillofac Implants* 1997;12:88-94.
  91. Wallace SS, Froum SJ, Cho SC, et al. Sinus augmentation utilizing anorganic bovine bone (Bio-Oss) with absorbable and nonabsorbable membranes placed over the lateral window: Histomorphometric and clinical analyses. *Int J Periodontics Restorative Dent* 2005; 25:551-559.
  92. Tarnow DP, Wallace SS, Froum SJ, et al. Histologic and clinical comparison of bilateral sinus floor elevations with and without barrier membrane placement in 12 patients: Part 3 of an ongoing prospective study. *Int J Periodontics Restorative Dent* 2000;20:117-125.
  93. Moy PK, Lundgren S, Holmes RE. Maxillary sinus augmentation: Histomorphometric analysis of graft materials for maxillary sinus floor augmentation. *J Oral Maxillofac Surg* 1993;51:857-862.
  94. Wheeler SL. Sinus augmentation for dental implants: The use of alloplastic materials. *J Oral Maxillofac Surg* 1997;55:1287-1293.
  95. Wheeler SL, Holmes RE, Calhoun CJ. Six-year clinical and histologic study of sinus-lift grafts. *Int J Oral Maxillofac Implants* 1996;11:26-34.
  96. Sandler NA, Johns FR, Braun TW. Advances in the management of acute and chronic sinusitis. *J Oral Maxillofac Surg* 1996;54:1005-1013.
  97. Zinreich SJ, Kennedy DW, Rosenbaum AE, et al. Paranasal sinuses: CT imaging requirements for endoscopic surgery. *Radiology* 1987;163:769-775.
  98. Misch CE. The maxillary sinus and sinus graft surgery. In: Misch CE, ed. *Contemporary Implant Dentistry*, 2nd ed. St. Louis: Mosby; 1999:469-495.
  99. Tidwell JK, Blijdorp PA, Stoelinga PJ, et al. Composite grafting of the maxillary sinus for placement of endosteal implants. A preliminary report of 48 patients. *Int J Oral Maxillofac Surg* 1992;21:204-209.
  100. McAllister BS, Margolin MD, Cogan AG, et al. Eighteen-month radiographic and histologic evaluation of sinus grafting with anorganic bovine bone in the chimpanzee. *Int J Oral Maxillofac Implants* 1999;14: 361-368.



101. Regev E, Smith RA, Perrott DH, et al. Maxillary sinus complications related to endosseous implants. *Int J Oral Maxillofac Implants* 1995;10:451-461.
102. Misch CM. The pharmacologic management of maxillary sinus elevation surgery. *J Oral Implantol* 1992; 18:15-23.
103. Zinner ID, Small SA, Panno FV, et al. Provisional and definitive prostheses following sinus lift and augmentation procedures. *Implant Dent* 1994;3:24-28.
104. Peterson LJ. Antibiotic prophylaxis against wound infections in oral and maxillofacial surgery. *J Oral Maxillofac Surg* 1990;48:617-620.
105. Hurley LA, Stinchfield FE, Bassett AL, et al. The role of soft tissues in osteogenesis. An experimental study of canine spine fusions. *J Bone Joint Surg Am* 1959; 41-A:1243-1254.
106. Dahlin C, Sennerby L, Lekholm U, et al. Generation of new bone around titanium implants using a membrane technique: An experimental study in rabbits. *Int J Oral Maxillofac Implants* 1989;4:19-25.
107. Nyman S, Lindhe J, Karring T, Rylander H. New attachment following surgical treatment of human periodontal disease. *J Clin Periodontol* 1982;9:290-296.
108. Dahlin C, Gottlow J, Linde A, Nyman S. Healing of maxillary and mandibular bone defects using a membrane technique. An experimental study in monkeys. *Scand J Plast Reconstr Surg Hand Surg* 1990;24:13-19.
109. Buser D, Dula K, Belser U, et al. Localized ridge augmentation using guided bone regeneration. I. Surgical procedure in the maxilla. *Int J Periodontics Restorative Dent* 1993;13:29-45.
110. Buser D, Dula K, Belser UC, et al. Localized ridge augmentation using guided bone regeneration. II. Surgical procedure in the mandible. *Int J Periodontics Restorative Dent* 1995;15:10-29.
111. Jovanovic SA, Schenk RK, Orsini M, Kenney EB. Supracrestal bone formation around dental implants: An experimental dog study. *Int J Oral Maxillofac Implants* 1995;10:23-31.
112. Simion M, Jovanovic SA, Tinti C, et al. Long-term evaluation of osseointegrated implants inserted at the time or after vertical ridge augmentation. A retrospective study on 123 implants with 1-5 year follow-up. *Clin Oral Implants Res* 2001;12:35-45.
113. Adell R, Lekholm U, Grondahl K, et al. Reconstruction of severely resorbed edentulous maxillae using osseointegrated fixtures in immediate autogenous bone grafts. *Int J Oral Maxillofac Implants* 1990;5: 233-246.
114. Dahlin C, Lekholm U, Linde A. Membrane-induced bone augmentation at titanium implants. A report on ten fixtures followed from 1 to 3 years after loading. *Int J Periodontics Restorative Dent* 1991;11: 273-281.
115. Nevins M, Mellonig JT, Clem DS III, et al. Implants in regenerated bone: Long-term survival. *Int J Periodontics Restorative Dent* 1998;18:34-45.
116. Bartee BK. A membrane and graft technique for ridge maintenance using high-density polytetrafluoroethylene membrane (n-PTFE) and hydroxylapatite: Report of four cases. *Tex Dent J* 1995;112:7, 9, 11-16.
117. Bartee BK. The use of high-density polytetrafluoroethylene membrane to treat osseous defects: Clinical reports. *Implant Dent* 1995;4:21-26.
118. Jovanovic SA, Nevins M. Bone formation utilizing titanium-reinforced barrier membranes. *Int J Periodontics Restorative Dent* 1995;15:56-69.
119. von Arx T, Hardt N, Wallkamm B. The TIME technique: A new method for localized alveolar ridge augmentation prior to placement of dental implants. *Int J Oral Maxillofac Implants* 1996;11:387-394.
120. Hardwick R, Hayes BK, Flynn C. Devices for dentoalveolar regeneration: An up-to-date literature review. *J Periodontol* 1995;66:495-505.
121. Bartee BK, Carr JA. Evaluation of a high-density polytetrafluoroethylene (n-PTFE) membrane as a barrier material to facilitate guided bone regeneration in the rat mandible. *J Oral Implantol* 1995;21:88-95.
122. Boyne PJ. Animal studies of application of rhBMP-2 in maxillofacial reconstruction. *Bone* 1996;19:83S-92S.
123. Schenk RK, Buser D, Hardwick WR, et al. Healing pattern of bone regeneration in membrane-protected defects: A histologic study in the canine mandible. *Int J Oral Maxillofac Implants* 1994;9:13-29.
124. Machtei EE. The effect of membrane exposure on the outcome of regenerative procedures in humans: A meta-analysis. *J Periodontol* 2001;72:512-516.
125. Simion M, Baldoni M, Rossi P, et al. A comparative study of the effectiveness of e-PTFE membranes with and without early exposure during the healing period. *Int J Periodontics Restorative Dent* 1994;14: 166-180.
126. Rasmusson L, Sennerby L, Lundgren D, et al. Morphological and dimensional changes after barrier removal in bone formed beyond the skeletal borders at titanium implants. A kinetic study in the rabbit tibia. *Clin Oral Implants Res* 1997;8:103-116.
127. Nowzari H, London R, Slots J. The importance of periodontal pathogens in guided periodontal tissue regeneration and guided bone regeneration. *Comp Contin Educ Dent* 1995;16:1042, 1044, 1046 passim; quiz 1058.
128. Nowzari H, Matian F, Slots J. Periodontal pathogens on polytetrafluoroethylene membrane for guided tissue regeneration inhibit healing. *J Clin Periodontol* 1995;22:469-474.
129. Nowzari H, Slots J. Microbiologic and clinical study of polytetrafluoroethylene membranes for guided bone regeneration around implants. *Int J Oral Maxillofac Implants* 1995;10:67-73.
130. Hutmacher D, Hurzeler MB, Schliephake H. A review of material properties of biodegradable and bioresorbable polymers and devices for GTR and GBR applications. *Int J Oral Maxillofac Implants* 1996;11: 667-678.
131. Owens KW, Yukna RA. Collagen membrane resorption in dogs: A comparative study. *Implant Dent* 2001; 10:49-58.
132. Zhao S, Pinholt EM, Madsen JE, Donath K. Histological evaluation of different biodegradable and non-biodegradable membranes implanted subcutaneously in rats. *J Craniomaxillofac Surg* 2000;28:116-122.
133. Marinucci L, Lilli C, Baroni T, et al. In vitro comparison of bioabsorbable and non-resorbable membranes in bone regeneration. *J Periodontol* 2001;72: 753-759.
134. Hurzeler MB, Quinones CR, Schupbach P. Guided bone regeneration around dental implants in the atrophic alveolar ridge using a bioresorbable barrier. An experimental study in the monkey. *Clin Oral Implants Res* 1997;8:323-331.
135. Wang HL, O'Neal RB, Thomas CL, et al. Evaluation of an absorbable collagen membrane in treating



- Class II furcation defects. *J Periodontol* 1994;65:1029-1036.
136. Lundgren D, Sennerby L, Falk H, et al. The use of a new bioresorbable barrier for guided bone regeneration in connection with implant installation. Case reports. *Clin Oral Implants Res* 1994;5:177-184.
  137. Polson AM, Garrett S, Stoller NH, et al. Guided tissue regeneration in human furcation defects after using a biodegradable barrier: A multi-center feasibility study. *J Periodontol* 1995;66:377-385.
  138. Vernino AR, Ringeisen TA, Wang HL, et al. Use of biodegradable polylactic acid barrier materials in the treatment of grade II periodontal furcation defects in humans – Part I: A multicenter investigative clinical study. *Int J Periodontics Restorative Dent* 1998;18:572-585.
  139. Sevor JJ, Meffert RM, Cassingham RJ. Regeneration of dehiscenced alveolar bone adjacent to endosseous dental implants utilizing a resorbable collagen membrane: Clinical and histologic results. *Int J Periodontics Restorative Dent* 1993;13:71-83.
  140. Stein MD, Salkin LM, Freedman AL, et al. Collagen sponge as a topical hemostatic agent in mucogingival surgery. *J Periodontol* 1985;56:35-38.
  141. Hutmacher DW, Kirsch A, Ackermann KL, et al. A tissue engineered cell-occlusive device for hard tissue regeneration – A preliminary report. *Int J Periodontics Restorative Dent* 2001;21:49-59.
  142. Buser D, Dula K, Hess D, et al. Localized ridge augmentation with autografts and barrier membranes. *Periodontol* 2000 1999;19:151-163.
  143. McGinnis M, Larsen P, Miloro M, et al. Comparison of resorbable and nonresorbable guided bone regeneration materials: A preliminary study. *Int J Oral Maxillofac Implants* 1998;13:30-35.
  144. Mellonig JT, Nevins M, Sanchez R. Evaluation of a bioabsorbable physical barrier for guided bone regeneration. Part I. Material alone. *Int J Periodontics Restorative Dent* 1998;18:139-149.
  145. Simion M, Scarano A, Gionso L, Piattelli A. Guided bone regeneration using resorbable and nonresorbable membranes: A comparative histologic study in humans. *Int J Oral Maxillofac Implants* 1996;11:735-742.
  146. Sandberg E, Dahlin C, Linde A. Bone regeneration by the osteopromotion technique using bioabsorbable membranes: An experimental study in rats. *J Oral Maxillofac Surg* 1993;51:1106-1114.
  147. Jovanovic SA. Protected space development for bone formation using reinforced barrier membranes In: Nevins M, Mellonig JT, eds. *Implant Therapy: Clinical Approaches and Evidence of Success*. Chicago: Quintessence Publishing; 1998:91-98.
  148. Hurzeler MB, Strub JR. Guided bone regeneration around exposed implants: A new bioresorbable device and bioresorbable membrane pins. *Pract Periodontics Aesthet Dent* 1995;7:37-47; quiz 50.
  149. Furusawa T, Mizunuma K. Osteoconductive properties and efficacy of resorbable bioactive glass as a bone-grafting material. *Implant Dent* 1997;6:93-101.
  150. Berglundh T, Lindhe J. Healing around implants placed in bone defects treated with Bio-Oss. An experimental study in the dog. *Clin Oral Implants Res* 1997;8:117-124.
  151. Hall EE, Meffert RM, Hermann JS, et al. Comparison of bioactive glass to demineralized freeze-dried bone allograft in the treatment of intrabony defects around implants in the canine mandible. *J Periodontol* 1999;70:526-535.
  152. Palmer P, Palmer R. Implant surgery to overcome anatomical difficulties. *Br Dent J* 1999;187:532-540.
  153. Mowlem R. Cancellous chip bone grafts: Report on 75 cases. *Lancet* 1944;2:746-748.
  154. Mellonig JT. Autogenous and allogeneic bone grafts in periodontal therapy. *Crit Rev Oral Biol Med* 1992;3:333-352.
  155. Mulliken JB, Glowacki J. Induced osteogenesis for repair and construction in the craniofacial region. *Plast Reconstr Surg* 1980;65:553-560.
  156. McEwen W. Intrahuman bone grafting and reimplantation of bone. *Ann Surg* 1909;50:959-968.
  157. Hauschka PV, Mavrakos AE, Iafrafi MD, et al. Growth factors in bone matrix. Isolation of multiple types by affinity chromatography on heparin-sepharose. *J Biol Chem* 1986;261:12665-12674.
  158. Sampath TK, Muthukumaran N, Reddi AH. Isolation of osteogenin, an extracellular matrix-associated, bone-inductive protein, by heparin affinity chromatography. *Proc Natl Acad Sci USA* 1987;84:7109-7113.
  159. Shigeyama Y, D'Errico JA, Stone R, et al. Commercially-prepared allograft material has biological activity in vitro. *J Periodontol* 1995;66:478-487.
  160. Urist MR, Huo YK, Brownell AG, et al. Purification of bovine bone morphogenetic protein by hydroxyapatite chromatography. *Proc Natl Acad Sci USA* 1984;81:371-375.
  161. Becker W, Urist MR, Tucker LM, et al. Human demineralized freeze-dried bone: Inadequate induced bone formation in athymic mice. A preliminary report. *J Periodontol* 1995;66:822-828.
  162. Schwartz Z, Mellonig JT, Carnes DL Jr., et al. Ability of commercial demineralized freeze-dried bone allograft to induce new bone formation. *J Periodontol* 1996;67:918-926.
  163. Whittaker JM, James RA, Lozada J, et al. Histological response and clinical evaluation of heterograft and allograft materials in the elevation of the maxillary sinus for the preparation of endosteal dental implant sites. Simultaneous sinus elevation and root form implantation: An eight-month autopsy report. *J Oral Implantol* 1989;15:141-144.
  164. Cochran DL, Douglas HB. Augmentation of osseous tissue around nonsubmerged endosseous dental implants. *Int J Periodontics Restorative Dent* 1993;13:506-519.
  165. Buck BE, Resnick L, Shah SM, et al. Human immunodeficiency virus cultured from bone. Implications for transplantation. *Clin Orthop* 1990;(Feb)251:249-253.
  166. Mellonig JT, Prewett AB, Moyer MP. HIV inactivation in a bone allograft. *J Periodontol* 1992;63:979-983.
  167. Hench LL. Bioactive materials: The potential for tissue regeneration. *J Biomed Mater Res* 1998;41:511-518.
  168. Burchardt H. The biology of bone graft repair. *Clin Orthop* 1983;174:28-42.
  169. Pinholt EM, Bang G, Haanaes HR. Alveolar ridge augmentation by osteoinduction in rats. *Scand J Dent Res* 1990;98:434-441.
  170. Furusawa T, Mizunuma K. Osteoconductive properties and efficacy of resorbable bioactive glass as a bone grafting material. *Implant Dent* 1997;6:93-101.

171. Tadjoein ES, De Lange GL, Holzmann PJ, et al. Histological observations on biopsies harvested following sinus floor elevation using a bioactive glass material of narrow size range. *Clin Oral Implants Res* 2000;11:334-344.
172. Hamilton D. On sponge grafting. *J Anat Physiol* 1881;27:385-414.
173. Han T, Carranza FA Jr., Kenney EB. Calcium phosphate ceramics in dentistry: A review of the literature. *J West Soc Periodontol Periodontol Abstr* 1984;32:88-108.
174. Jarcho M. Biomaterial aspects of calcium phosphates. Properties and applications. *Dent Clin North Am* 1986;30:25-47.
175. Roy DM, Linnehan SK. Hydroxyapatite formed from coral skeletal carbonate by hydrothermal exchange. *Nature* 1974;247:220-222.
176. Schmitt JM, Hwang K, Winn SR, et al. Bone morphogenetic proteins: An update on basic biology and clinical relevance. *J Orthop Res* 1999;17:269-278.
177. Perry CR. Bone repair techniques, bone graft, and bone graft substitutes. *Clin Orthop* 1999;(Mar)252:71-86.
178. White E, Shors EC. Biomaterial aspects of Interpore-200 porous hydroxyapatite. *Dent Clin North Am* 1986;30:49-67.
179. Frame JW, Rout PG, Browne RM. Ridge augmentation using solid and porous hydroxylapatite particles with and without autogenous bone or plaster. *J Oral Maxillofac Surg* 1987;45:771-778.
180. Senn N. On the healing of aseptic bone cavities by implantation of aseptic decalcified bone. *Am J Med Sci* 1889;98:219.
181. Wallace SS, Froum SJ, Tarnow DP. Histologic evaluation of a sinus elevation procedure: A clinical report. *Int J Periodontics Restorative Dent* 1996;16:46-51.
182. Thaller SR, Hoyt J, Borjeson K, et al. Reconstruction of calvarial defects with anorganic bovine bone mineral (Bio-Oss) in a rabbit model. *J Craniofac Surg* 1993;4:79-84.
183. Krauser JT, Rohrer MD, Wallace SS. Human histologic and histomorphometric analysis comparing OsteoGraf/N with PepGen P-15 in the maxillary sinus elevation procedure: A case report. *Implant Dent* 2000;9:298-302.
184. Bhatnagar RS, Qian JJ, Wedrychowska A, et al. Design of biomimetic habitats for tissue engineering with P-15, a synthetic peptide analogue of collagen. *Tissue Eng* 1999;5:53-65.
185. Scarano A, Degidi M, Iezzi G, et al. Maxillary sinus augmentation with different biomaterials: A comparative histologic and histomorphometric study in man. *Implant Dent* 2006;15:197-207.
186. Degidi M, Piattelli M, Scarano A, et al. Maxillary sinus augmentation with a synthetic cell-binding peptide: Histological and histomorphometrical results in humans. *J Oral Implantol* 2004;30:376-383.
187. Misch CM. Comparison of intraoral donor sites for onlay grafting prior to implant placement. *Int J Oral Maxillofac Implants* 1997;12:767-776.
188. Pikos MA. Block autografts for localized ridge augmentation: Part I. The posterior maxilla. *Implant Dent* 1999;8:279-285.
189. Pikos MA. Block autografts for localized ridge augmentation: Part II. The posterior mandible. *Implant Dent* 2000;9:67-75.
190. de Carvalho PS, Vasconcellos LW, Pi J. Influence of bed preparation on the incorporation of autogenous bone grafts: A study in dogs. *Int J Oral Maxillofac Implants* 2000;15:565-570.
191. Lin KY, Bartlett SP, Yaremchuk MJ, et al. The effect of rigid fixation on the survival of onlay bone grafts: An experimental study. *Plast Reconstr Surg* 1990;86:449-456.
192. Urbani G, Lombardo G, Santi E, Tarnow D. Localized ridge augmentation with chin grafts and resorbable pins: Case reports. *Int J Periodontics Restorative Dent* 1998;18:363-375.
193. Breine U, Brånemark PI. Reconstruction of alveolar jaw bone. An experimental and clinical study of immediate and preformed autologous bone grafts in combination with osseointegrated implants. *Scand J Plast Reconstr Surg* 1980;14:23-48.
194. Isaksson S, Alberius P. Maxillary alveolar ridge augmentation with onlay bone-grafts and immediate endosseous implants. *J Craniomaxillofac Surg* 1992;20:2-7.
195. Jensen J, Sindet-Pedersen S. Autogenous mandibular bone grafts and osseointegrated implants for reconstruction of the severely atrophied maxilla: A preliminary report. *J Oral Maxillofac Surg* 1991;49:1277-1287.
196. Majzoub Z, Berengo M, Giardino R, et al. Role of intramarrow penetration in osseous repair: A pilot study in the rabbit calvaria. *J Periodontol* 1999;70:1501-1510.
197. Albrektsson T. In vivo studies of bone grafts. The possibility of vascular anastomoses in healing bone. *Acta Orthop Scand* 1980;51:9-17.
198. Albrektsson T. Repair of bone grafts. A vital microscopic and histological investigation in the rabbit. *Scand J Plast Reconstr Surg* 1980;14:1-12.
199. Burchardt H, Enneking WF. Transplantation of bone. *Surg Clin North Am* 1978;58:403-427.
200. Keller EE, Tolman DE, Eckert S. Surgical-prosthetic reconstruction of advanced maxillary bone compromise with autogenous onlay block bone grafts and osseointegrated endosseous implants: A 12-year study of 32 consecutive patients. *Int J Oral Maxillofac Implants* 1999;14:197-209.
201. Sailer HF. A new method of inserting endosseous implants in totally atrophic maxillae. *J Craniomaxillofac Surg* 1989;17:299-305.
202. Verhoeven JW, Cune MS, Terlou M, et al. The combined use of endosteal implants and iliac crest onlay grafts in the severely atrophic mandible: A longitudinal study. *Int J Oral Maxillofac Surg* 1997;26:351-357.
203. Proussaefs P, Lozada J, Kleinman A, et al. The use of ramus autogenous block grafts for vertical alveolar ridge augmentation and implant placement: A pilot study. *Int J Oral Maxillofac Implants* 2002;17:238-248.
204. Zins JE, Whitaker LA. Membranous versus endochondral bone: Implications for craniofacial reconstruction. *Plast Reconstr Surg* 1983;72:778-785.
205. Misch CM, Misch CE, Resnik RR, et al. Reconstruction of maxillary alveolar defects with mandibular symphysis grafts for dental implants: A preliminary procedural report. *Int J Oral Maxillofac Implants* 1992;7:360-366.
206. Raghoobar GM, Batenburg RH, Vissink A, et al. Augmentation of localized defects of the anterior maxillary ridge with autogenous bone before

- insertion of implants. *J Oral Maxillofac Surg* 1996;54:1180-1185.
207. Widmark G, Andersson B, Ivanoff CJ. Mandibular bone graft in the anterior maxilla for single-tooth implants. Presentation of surgical method. *Int J Oral Maxillofac Surg* 1997;26:106-109.
  208. Jardini MA, De Marco AC, Lima LA. Early healing pattern of autogenous bone grafts with and without e-PTFE membranes: A histomorphometric study in rats. *Oral Surg Oral Med Oral Pathol Oral Radiol Endod* 2005;100:666-673.
  209. Jensen OT, Greer RO Jr., Johnson L, et al. Vertical guided bone-graft augmentation in a new canine mandibular model. *Int J Oral Maxillofac Implants* 1995;10:335-344.
  210. Burchardt H. The biology of bone graft repair. *Clin Orthop Relat Res* 1983;Apr;(174):28-42.
  211. Enneking WF, Eady JL, Burchardt H. Autogenous cortical bone grafts in the reconstruction of segmental skeletal defects. *J Bone Joint Surg Am* 1980;62:1039-1058.
  212. Matsumoto MA, Filho HN, Francischone E, Conso-laro A. Microscopic analysis of reconstructed maxillary alveolar ridges using autogenous bone grafts from the chin and iliac crest. *Int J Oral Maxillofac Implants* 2002;17:507-516.
  213. Proussaefs P, Lozada J, Rohrer MD. A clinical and histologic evaluation of a block onlay graft in conjunction with autogenous particulate and inorganic bovine mineral (Bio-Oss): A case report. *Int J Periodontics Restorative Dent* 2002;22:567-573.
  214. Keith JD Jr. Localized ridge augmentation with a block allograft followed by secondary implant placement: A case report. *Int J Periodontics Restorative Dent* 2004;24:11-17.
  215. Leonetti JA, Koup R. Localized maxillary ridge augmentation with a block allograft for dental implant placement: Case reports. *Implant Dent* 2003;12:217-224.
  216. Lyford RH, Mills MP, Knapp CI, et al. Clinical evaluation of freeze-dried block allografts for alveolar ridge augmentation: A case series. *Int J Periodontics Restorative Dent* 2003;23:417-425.
  217. Malmquist J. Osteopromotion in osseointegration techniques: The use of membrane technique to regenerate bone with endosseous implants for maxillofacial reconstruction In: Block MS, Kent JN, eds. *Endosseous Implants for Maxillofacial Reconstruction*. Philadelphia: W.B. Saunders Company; 1995:437.
  218. Malmquist JP. Successful implant restoration with the use of barrier membranes. *J Oral Maxillofac Surg* 1999;57:1114-1116.
  219. Clarizio LF. Successful implant restoration without the use of membrane barriers. *J Oral Maxillofac Surg* 1999;57:1117-1121.
  220. Doblin JM, Salkin LM, Mellado JR, et al. A histologic evaluation of localized ridge augmentation utilizing DFDBA in combination with e-PTFE membranes and stainless steel bone pins in humans. *Int J Periodontics Restorative Dent* 1996;16:120-129.
  221. Jovanovic SA, Spiekermann H, Richter EJ. Bone regeneration around titanium dental implants in dehiscence defect sites: A clinical study. *Int J Oral Maxillofac Implants* 1992;7:233-245.
  222. ten Bruggenkate CM, Kraaijenhagen HA, van der Kwast WA, et al. Autogenous maxillary bone grafts in conjunction with placement of I.T.I. endosseous im-  
plants. A preliminary report. *Int J Oral Maxillofac Surg* 1992;21:81-84.
  223. Duncan JM, Westwood RM. Ridge widening for the thin maxilla: A clinical report. *Int J Oral Maxillofac Implants* 1997;12:224-227.
  224. Scipioni A, Bruschi GB, Calesini G. The edentulous ridge expansion technique: A five-year study. *Int J Periodontics Restorative Dent* 1994;14:451-459.
  225. Vercellotti T. Piezoelectric surgery in implantology: A case report – A new piezoelectric ridge expansion technique. *Int J Periodontics Restorative Dent* 2000;20:358-365.
  226. Sethi A, Kaus T. Maxillary ridge expansion with simultaneous implant placement: 5-year results of an ongoing clinical study. *Int J Oral Maxillofac Implants* 2000;15:491-499.
  227. Engelke WG, Diederichs CG, Jacobs HG, Deckwer I. Alveolar reconstruction with splitting osteotomy and microfixation of implants. *Int J Oral Maxillofac Implants* 1997;12:310-318.
  228. Simion M, Baldoni M, Zaffe D. Jawbone enlargement using immediate implant placement associated with a split-crest technique and guided tissue regeneration. *Int J Periodontics Restorative Dent* 1992;12:462-473.
  229. Codivilla A. On the means of lengthening, in the lower limbs, the muscles and tissues which are shortened through deformity. *Clin Orthop* 1994;(Apr)301:4-9.
  230. Block MS, Akin R, Chang A, et al. Skeletal and dental movements after anterior maxillary advancement using implant-supported distraction osteogenesis in dogs. *J Oral Maxillofac Surg* 1997;55:1433-1439.
  231. Block MS, Almerico B, Crawford C, et al. Bone response to functioning implants in dog mandibular alveolar ridges augmented with distraction osteogenesis. *Int J Oral Maxillofac Implants* 1998;13:342-351.
  232. Ilizarov GA. The tension-stress effect on the genesis and growth of tissues. Part I. The influence of stability of fixation and soft-tissue preservation. *Clin Orthop* 1989;(Jan)238:249-281.
  233. Oda T, Sawaki Y, Ueda M. Experimental alveolar ridge augmentation by distraction osteogenesis using a simple device that permits secondary implant placement. *Int J Oral Maxillofac Implants* 2000;15:95-102.
  234. Takahashi T, Funaki K, Shintani H, Haruoka T. Use of horizontal alveolar distraction osteogenesis for implant placement in a narrow alveolar ridge: A case report. *Int J Oral Maxillofac Implants* 2004;19:291-294.
  235. Ilizarov GA. Basic principles of transosseous compression and distraction osteosynthesis (in Russian). *Ortop Traumatol Protez* 1971;32:7-15.
  236. Ilizarov GA. The tension-stress effect on the genesis and growth of tissues: Part II. The influence of the rate and frequency of distraction. *Clin Orthop* 1989;(Feb)239:263-285.
  237. Chiapasco M, Romeo E, Vogel G. Vertical distraction osteogenesis of edentulous ridges for improvement of oral implant positioning: A clinical report of preliminary results. *Int J Oral Maxillofac Implants* 2001;16:43-51.
  238. Gaggl A, Schultes G, Karcher H. Vertical alveolar ridge distraction with prosthetic treatable distractors: A clinical investigation. *Int J Oral Maxillofac Implants* 2000;15:701-710.



239. McAllister BS. Histologic and radiographic evidence of vertical ridge augmentation utilizing distraction osteogenesis: 10 consecutively placed distractors. *J Periodontol* 2001;72:1767-1779.
240. Hidding J, Lazar F, Zoller J. The vertical distraction of the alveolar bone. *J Craniomaxillofac Surg* 1998; 26:72-73.
241. McAllister BS, Gaffaney TE. Distraction osteogenesis for vertical bone augmentation prior to oral implant reconstruction. *Periodontol* 2000 2003;33:54-66.
242. Bavitz JB, Payne JB, Dunning D, et al. The use of distraction osteogenesis to induce new suprabony periodontal attachment in the beagle dog. *Int J Periodontics Restorative Dent* 2000;20:596-603.
243. Jensen OT, Cockrell R, Kuhike L, et al. Anterior maxillary alveolar distraction osteogenesis: A prospective 5-year clinical study. *Int J Oral Maxillofac Implants* 2002;17:52-68.
244. Proussaefs P, Lozada J. The use of resorbable collagen membrane in conjunction with autogenous bone graft and inorganic bovine mineral for buccal/labial alveolar ridge augmentation: A pilot study. *J Prosthet Dent* 2003;90:530-538.
245. Chiapasco M, Consolo U, Bianchi A, et al. Alveolar distraction osteogenesis for the correction of vertically deficient edentulous ridges: A multicenter prospective study on humans. *Int J Oral Maxillofac Implants* 2004;19:399-407.
246. Taba M Jr., Jin Q, Sugai JV, Giannobile WV. Current concepts in periodontal bioengineering. *Orthod Craniofac Res* 2005;8:292-302.
247. Howell TH, Fiorellini J, Jones A, et al. A feasibility study evaluating rhBMP-2/absorbable collagen sponge device for local alveolar ridge preservation or augmentation. *Int J Periodontics Restorative Dent* 1997;17: 124-139.
248. Margolin MD, Cogan AG, Taylor M, et al. Maxillary sinus augmentation in the non-human primate: A comparative radiographic and histologic study between recombinant human osteogenic protein-1 and natural bone mineral. *J Periodontol* 1998;69: 911-919.
249. Boyne PJ, Nath R, Nakamura A. Human recombinant BMP-2 in osseous reconstruction of simulated cleft palate defects. *Br J Oral Maxillofac Surg* 1998; 36:84-90.
250. Becker W, Lynch SE, Lekholm U, et al. A comparison of ePTFE membranes alone or in combination with platelet-derived growth factors and insulin-like growth factor-I or demineralized freeze-dried bone in promoting bone formation around immediate extraction socket implants. *J Periodontol* 1992;63: 929-940.
251. Sampath TK, Reddi AH. Dissociative extraction and reconstitution of extracellular matrix components involved in local bone differentiation. *Proc Natl Acad Sci USA* 1981;78:7599-7603.
252. Wozney JM, Rosen V, Celeste AJ, et al. Novel regulators of bone formation: Molecular clones and activities. *Science* 1988;242:1528-1534.
253. Simion M, Rocchietta I, Kim D, et al. Vertical ridge augmentation by means of deproteinized bovine bone block and rhPDGF-BB. A histological study in a dog model. *Int J Periodontics Restorative Dent* 2006;26:415-423.
254. Nevins M, Giannobile WV, McGuire MK, et al. Platelet-derived growth factor stimulates bone fill and rate of attachment level gain: Results of a large multicenter randomized controlled trial. *J Periodontol* 2005; 76:2205-2215.
255. Marx RE, Carlson ER, Eichstaedt RM, et al. Platelet-rich plasma: Growth factor enhancement for bone grafts. *Oral Surg Oral Med Oral Pathol Oral Radiol Endod* 1998;85:638-646.
256. Sanchez AR, Sheridan PJ, Kupp LI. Is platelet-rich plasma the perfect enhancement factor? A current review. *Int J Oral Maxillofac Implants* 2003;18:93-103.
257. Lieberman JR, Daluiski A, Stevenson S, et al. The effect of regional gene therapy with bone morphogenetic protein-2-producing bone-marrow cells on the repair of segmental femoral defects in rats. *J Bone Joint Surg Am* 1999;81:905-917.
258. Breitbart AS, Grande DA, Mason JM, et al. Gene-enhanced tissue engineering: Applications for bone healing using cultured periosteal cells transduced retrovirally with the BMP-7 gene. *Ann Plast Surg* 1999; 42:488-495.
259. Jin QM, Anusaksathien O, Webb SA, et al. Gene therapy of bone morphogenetic protein for periodontal tissue engineering. *J Periodontol* 2003;74: 202-213.
260. Freed LE, Marquis JC, Nohria A, et al. Neocartilage formation in vitro and in vivo using cells cultured on synthetic biodegradable polymers. *J Biomed Mater Res* 1993;27:11-23.
261. Ishaug SL, Yaszemski MJ, Bizios R, et al. Osteoblast function on synthetic biodegradable polymers. *J Biomed Mater Res* 1994;28:1445-1453.
262. Malekzadeh R, Hollinger JO, Buck D, et al. Isolation of human osteoblast-like cells and in vitro amplification for tissue engineering. *J Periodontol* 1998;69: 1256-1262.
263. Stephan EB, Jiang D, Lynch S, et al. Anorganic bovine bone supports osteoblastic cell attachment and proliferation. *J Periodontol* 1999;70:364-369.
264. Stephan EB, Renjen R, Lynch SE, et al. Platelet-derived growth factor enhancement of a mineral-collagen bone substitute. *J Periodontol* 2000;71: 1887-1892.
265. De Kok IJ, Drapeau SJ, Young R, et al. Evaluation of mesenchymal stem cells following implantation in alveolar sockets: A canine safety study. *Int J Oral Maxillofac Implants* 2005;20:511-518.
266. Bruder SP, Kraus KH, Goldberg VM, et al. The effect of implants loaded with autologous mesenchymal stem cells on the healing of canine segmental bone defects. *J Bone Joint Surg Am* 1998;80:985-996.
267. Winn SR, Randolph G, Uludag H, et al. Establishing an immortalized human osteoprecursor cell line: OPC1. *J Bone Miner Res* 1999;14:1721-1733.

Correspondence: Dr. Bradley S. McAllister, 11525 S.W. Durham Rd., Suite D-6, Tigard, OR 97224. Fax: 503/968-5419; e-mail: mcallister@portlandimplantdentistry.com.

Accepted for publication July 21, 2006.